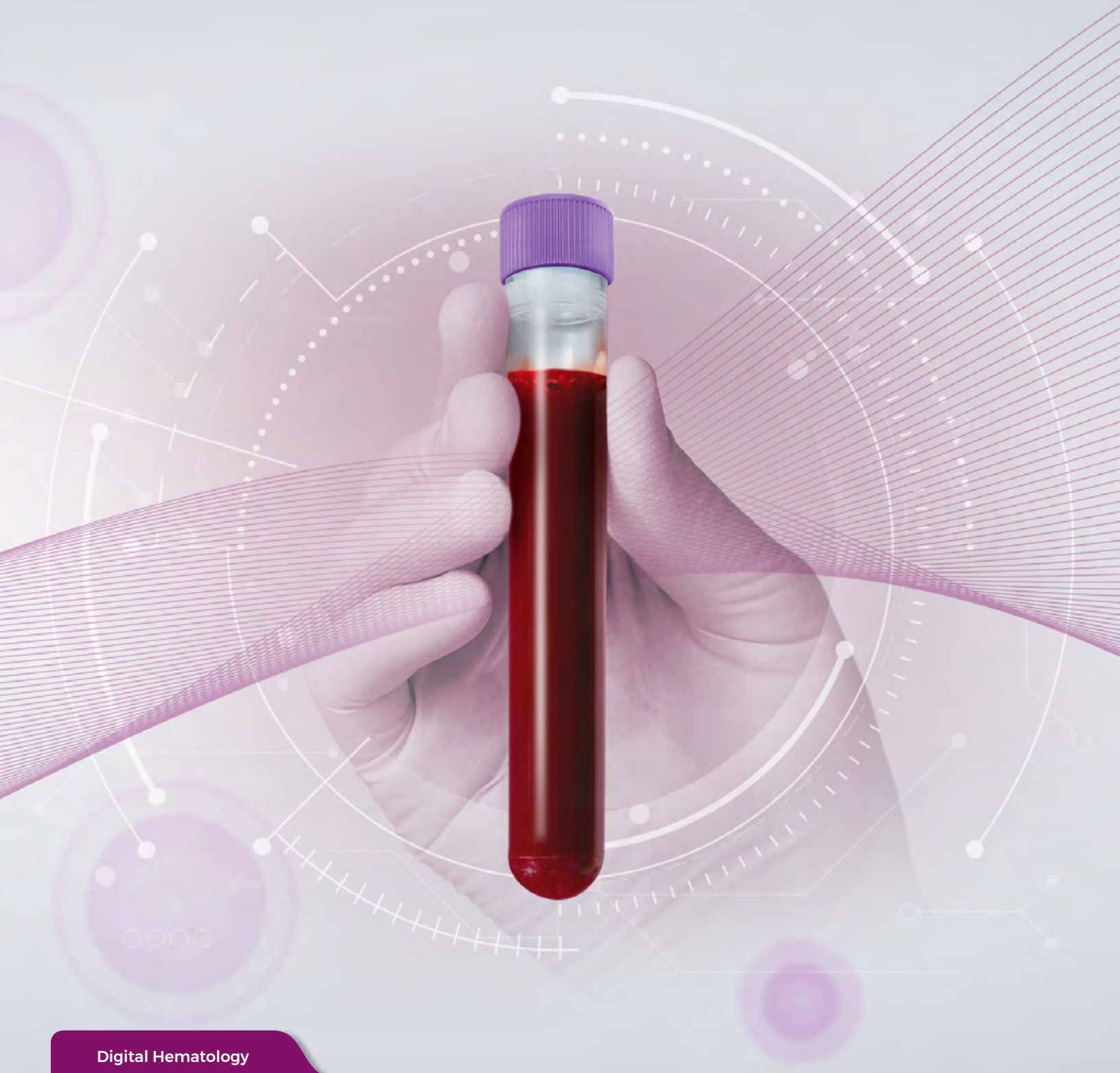



Digital Hematology

DxH 900 & 690T Hematology Analyzers Advanced Technology Casebook



**Dear Customer,**

In 2023, we celebrated the 110th birthday of Wallace H. Coulter, the person who first described the Coulter Principle (1956), a method for automated counting and sizing of microscopic particles. Coulter's innovations paved the way for the development of the complete blood count (CBC), the most commonly performed medical diagnostic test and an essential piece of patient data.

In the spirit of our core value of continuous improvement, the original impedance method described by Coulter has undergone generations of advances. Each progressive iteration has integrated many proprietary and/or distinct breakthroughs in areas including algorithm optimization, histogram derivation, precision fluidics, uniquely integrating baths, and the progression of digital over analog. Each optimization was focused on overcoming interferences and improving accuracy and precision, while reliably delivering more reportable results. Improvements were grounded in the modern lab's need for simplifying workflows touchpoints, reruns, reagents, and maintenance, all with more reportable results—and all fueled by our goal to advance the future of the CBC.

This educational case book was developed for hematology customers and by hematology DxH customers performing CBC analysis. In today's world of increasingly complex blood diseases, labs need to be able to do more with a single blood draw. It highlights how information can be obtained for every sample in the modern hematology lab during the process of CBC-differential analysis. When available, each case contains automated results from the DxH 900 or 690T hematology analyzer and manual 200-cell WBC differential results, including examples of digital cell images from the described case.

DxH results include numerical results, histograms, plots, flags, messages, and additional information such as @ - Research Use Only (RUO) parameters and Cell Population Data (CPD). RUO values and CPD values are used as supportive data to give confidence in the results that are reported. The DxH analyzer data presented in the casebook are intended for educational purposes and cannot be used for diagnostic purposes. Further analysis is dependent on a review by a pathologist in conjunction with ancillary studies and testing for final clinical diagnosis.

The limits for numerical results (H, L, cL, cH) presented in the case book are based on the user-defined reference ranges. Abnormal patterns in cases presented are simply a relative comparison to a normal whole blood specimen.

All operational and technological details for the hematology analyzers are described in the appropriate Instructions for Use documents and RUO addenda, which can be located at

www.beckmancoulter.com > **Support** > **Technical Documents**.

**Wallace H. Coulter**

To ensure clinical accuracy and relevance, the case studies have been carefully curated, edited, and reviewed by:

Kedar Inamdar, M.D., Ph.D.
Division Head, Hematopathology
Henry Ford Health, Detroit, MI, USA

We extend our heartfelt appreciation to our customers who have graciously dedicated their time and effort to gather these cases:

Mikeal Roussel, M.D., Ph.D.
University Hospital, Rennes, France

Maite Serrando, M.D., Ph.D.
Laboratori Clinic Territorial IAS-ICS
Girona, Spain

DxH 900/690T SYSTEM TECHNOLOGY

Introduction to DxH CBC

The complete blood count (CBC) is the fundamental analytical test that evaluates the three main cellular components: white blood cells (WBC), red blood cells (RBC), and platelets (PLT). CBC hematological analysis on the DxH 900/690T analyzer is based on the Coulter Principle.

Sample preparation begins with aspiration. Proper aspiration is verified at two blood detectors along the sample pathway and directed to either the WBC or RBC and PLT triple aperture bath system for sample preparation. The RBC diluent and WBC diluent/Lyse dilutions enter through a port at the bottom of the bath located tangential to a sloping surface. Tangential mixing reduces the introduction of bubbles, a common interference in mixing systems (Figure 1).

The bath system conducts real-time cellular counting with the ability to pivot analysis within the run. This allows the algorithm to extend counting while analysis is in progress in response to a cytopenia, which allows for more reportable and accurate results.

THE COULTER PRINCIPLE

The Coulter Principle is used to directly count and size cell volume by detecting and measuring changes in electrical resistance when a particle (such as a cell) in a conductive liquid passes through a small aperture as shown in Figure 2.

Figure 1. Tangential Mixing

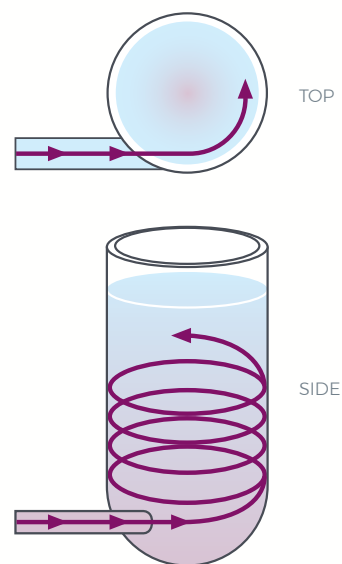
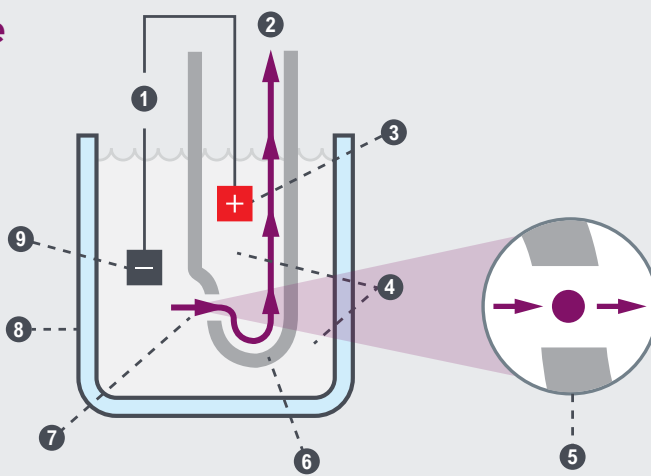


Figure 2. The Coulter Principle

The Coulter Principle

1. Aperture Current
2. Vacuum
3. Internal Electrode
4. Blood Cell Suspension
5. Detail of Aperture
6. Aperture Tube
7. Aperture
8. Sample Beaker
9. External Electrode

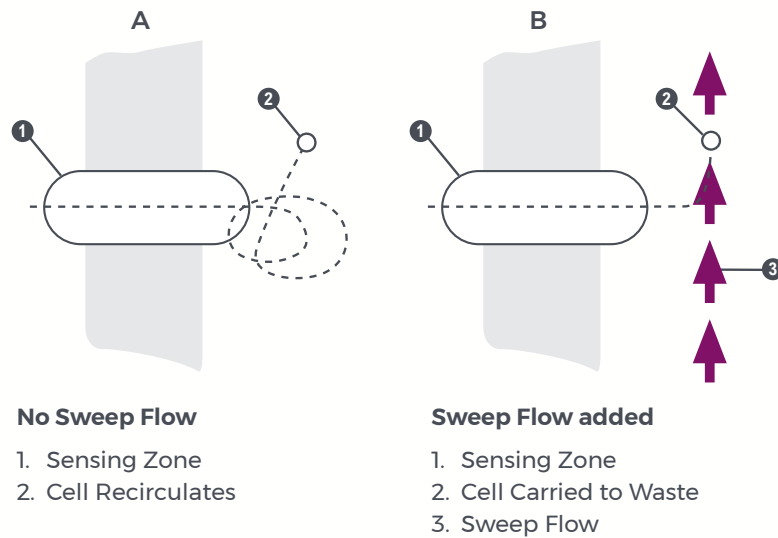


With certain patient populations and sample types, interferences can lower confidence in sample analysis resulting in increased flagging. With the enhanced Coulter Principle, sophisticated technology was created to overcome the challenges associated with these samples. The technologies are described below.

SWEEP FLOW

The RBC and PLT counts include the application of sweep flow to prevent the recirculation of cells behind the aperture (Figure 3A). Sweep flow, a steady stream of diluent that flows behind each of the three apertures during the sensing period, prevents cells from re-entering the sensing zone and being counted as platelets to deliver a more accurate count (Figure 3B).


Figure 3. Sweep Flow



TRIPLE COUNTING

Counting and sizing occurs in the RBC and WBC baths. Each bath has three discrete apertures that function as independent systems (Figure 4). This triplicate counting allows the system to look at each result individually. It helps to identify differences or interferences and then reports an average of the three channels. Having this triplicate counting is equivalent to running the sample three separate times in three separate environments, which can aid in counting more challenging samples.

Figure 4. Triple Counting



VOTING

To prevent data errors due to statistical outliers or obstructions that may block an aperture, the System Manager votes on data for WBC, RBC, MCV, RDW, PLT, and MPV, comparing data for all three apertures values as well as the histograms. The System Manager verifies that at least two apertures have produced data within an established statistical range of each other. A partial vote out of an individual aperture is not used in the averaged parameter value. Results are produced by averaging the parameters obtained from the apertures that are within the established statistical range (Figure 5).

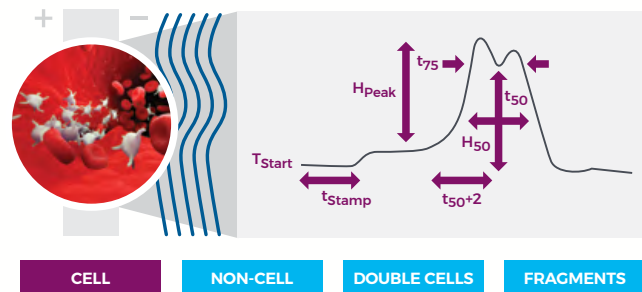
Figure 5. Triple Counting Data

		WBC	UWBC	RBC	MCV	RDW	PLT	MPV
APERTURE 1	<input checked="" type="checkbox"/>		4.059	4.617	94.65	13.06	153.5	10.14
APERTURE 2	<input checked="" type="checkbox"/>		3.916	4.643	93.75	13.06	155.7	10.15
APERTURE 3	<input checked="" type="checkbox"/>		4.042	4.610	93.61	13.17	163.0	9.99
	AVG	4.006	4.006	4.623	94.00	13.10	157.4	10.09

DIGITAL PULSE RECOGNITION

A unique feature of the DxH 900/690T technology occurs when cell counts, cell volumes, raw counts, and digital measurements are introduced to the System Manager. A cell signature using time and volume (count rate, wait time, and pulse width) is created. The pulse registry for each particle identifies the characteristics of a pulse, distinguishing between a cell, non-cell, double cells, and cell fragments (Figure 6).

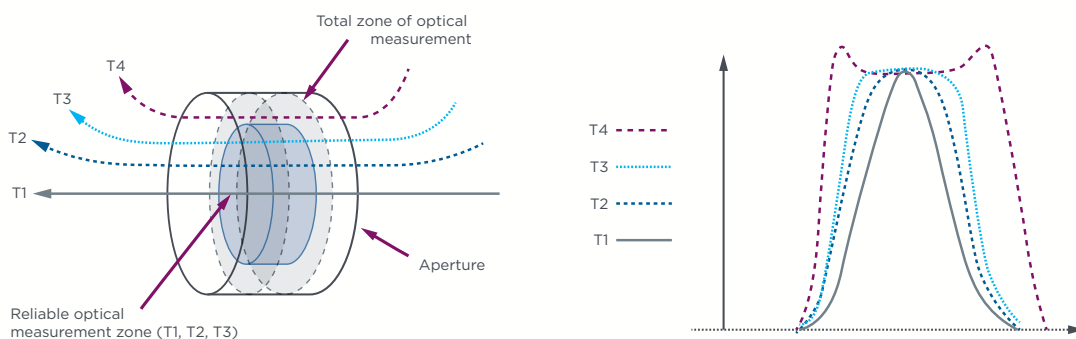
Figure 6. Pulse Characteristics



PULSE EDITING

Pulse Editing assists in accurate cell volume counting. When cells pass through the aperture near the edge or at an angle rather than at the center, they create atypical pulses. These atypical pulses are excluded from analysis because they distort the true size of the cell. This prevents the atypical pulses from influencing size measurement, providing a more accurate cell volume. Cell volume analysis is performed on the three cell types and subsets: RBCs, Reticulocytes and nRBCs, Platelets, WBC, and the WBC subpopulations to achieve superb RBC, PLT, and WBC differentials (Figure 7).

Figure 7. Coulter Digital Pulse Processing for Counting and Sizing






Platelet analysis applies a portion of the whole blood sample that is diluted, mixed, and counted using the digital Coulter Principle and sweep flow technology in the RBC bath. Platelet count and platelet volumes are directly measured. Platelet parameters—mean platelet volume (MPV) and Platelet distribution width (PDW)—are derived from the platelet histogram.

Data from both platelet and RBC analyses contribute to the formation of an extended platelet histogram. The extended platelet histogram includes all platelet and RBC data, creating a continuum of data for high-end interference analysis. Focusing on the data from 2-25 fL, a log-normal curve (Figure 8) and advanced algorithm applications are used to either include giant platelets or exclude interferences to provide high-quality, reliable RBC, PLT, and WBC differential results.

Based on the histogram feature analysis, the histogram is classified by its predominant pattern (e.g., normal, giant platelet, low-end interference). This classification allows for pattern-specific analysis that accounts for the unique characteristics of each pattern and the development of a final histogram to determine which channels are used for deriving the platelet parameters (Figure 8).

Figure 8. 256-Channel Extended Histogram Including PLT and RBC Parameters



For example, Figure 9A illustrates a normal platelet pattern where the final histogram is developed from the channels of the raw data curve between the left valley and the right valley. The final histogram of a giant platelet pattern (Figure 9B) is developed from the channels of the fitted curve between the left valley and a non-fixed end valley.

Figure 9A. Normal Platelet Pattern

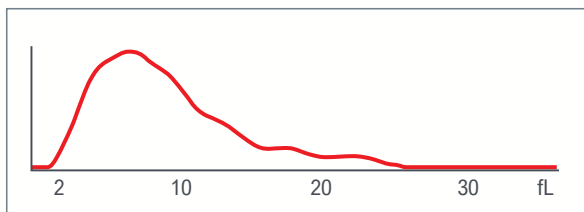
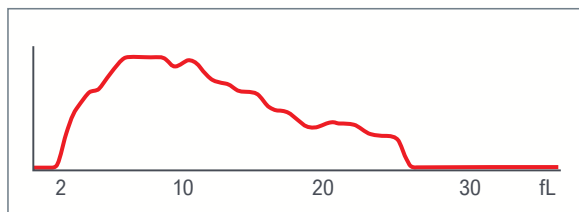


Figure 9B. Giant Platelet Pattern



HISTOGRAMS

The digital information from each WBC and RBC aperture is stored according to volume in 256-channel, size distribution histograms. Histograms show only the relative, not actual, number of cells in each size range.

It is important to not estimate the number of cells from the distribution curves.

To ensure that the size distribution curves accurately reflect the true cell population, the counting time on the DxH analyzer may be extended whenever the data accumulations are below a predetermined value.

Double-clicking a histogram displays a larger view of the histogram. Each histogram is drawn in a black line and the area under the line is shaded as follows:

WBC	light purple/lavender
RBC	reddish orange/pink
PLT	light green

HEMOGLOBINOMETRY

When measuring the amount of hemoglobin (Hgb) in a sample, the lytic reagent used for the WBC rapidly and simultaneously destroys the erythrocytes and converts a substantial proportion of the hemoglobin to a stable pigment while leaving leukocyte nuclei intact. Hgb is measured photometrically at 525 nm using the sample from the WBC analysis. A blank is introduced into the cuvette during each operating cycle. The Hgb blank provides a reference to which the sample signal is compared.

Patented algorithms automatically correct the RBC parameters when needed. RBC and MCV are corrected when $WBC > 140,000 \times 10^3 \text{ cells}/\mu\text{L}$; HGB and indices are corrected when $WBC > 11,000 \times 10^3 \text{ cells}/\mu\text{L}$. This positively impacts the accuracy of the hematocrit (HCT), mean corpuscular hemoglobin (MCH), and mean corpuscular hemoglobin concentration (MCHC).

Figure 11. Red Blood Cells

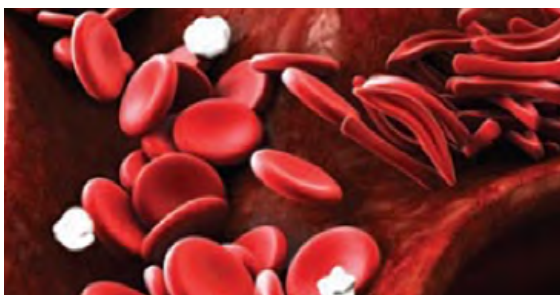
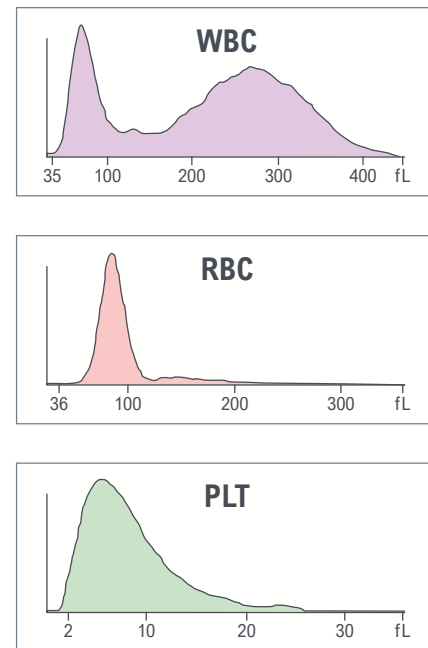


Figure 10. WBC, RBC and PLT Histogram





VCS - FLOW CYTOMETRY TECHNOLOGY

Beckman Coulter's Volume Conductivity and Light Scatter WBC differential technology uses multiple measurements including individual cell volume, high-frequency conductivity, and five angles of laser-light scatter. The combination of low-frequency current, high-frequency current, and light-scattering technology provides abundant cell-by-cell information, which is subsequently translated into scatterplots.

VOLUME ANALYSIS


Electronic Leukocyte Volume Analysis uses a direct current probe. This true-volume measurement allows for analysis of size and size variability.

CONDUCTIVITY ANALYSIS

Cell membranes act as conductors to high-frequency currents. The current, while passing through the cell membranes and through each cell interior, detects differences in the insulating properties of the cell components. The current characterizes the nuclear and granular constituents and the chemical composition of the cell interior as well as the nucleus-to-cytoplasmic (N:C) ratio.

LIGHT SCATTER ANALYSIS

Coulter's experience in flow cytometry dates back decades to Fulwyler's pioneering use of light scatter for cell analysis.¹ Loken et al.² and Jovin et al.³ discuss the relationship between particle size and refractivity to the angle of light scattered from a laser beam. Generations of flow cytometry instruments have directly benefited from the Coulter Principle. While Beckman Coulter is a world leader in fluorescence immunophenotyping, the DxH 900 and DxH 690T hematology analyzers were created with the intentional avoidance of fluorescence. The DxH 900 and 690T analyzer technology embraces five angles of light scatter for the generation of the WBC differential.





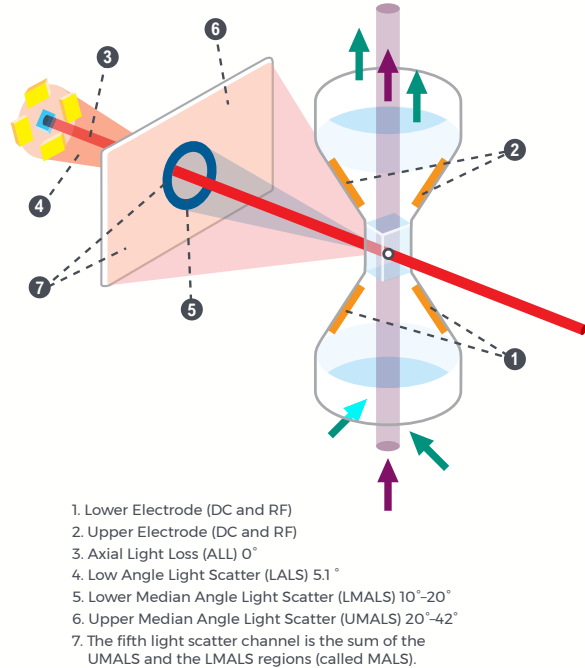
WBC DIFFERENTIAL ANALYSIS

Sample preparation occurs at the Diff Mix Chamber, where sample and reagents are added in the following order: Diff Lyse, blood, additional Diff Lyse followed by an air mix. Next, Diff preservative is added followed by a second air mix and an incubation period. The prepared sample is transferred to the Multi-transducer Module (MTM) where cells are counted in an isometric sample stream. The algorithm analysis separates the WBC into the major cellular populations.

The MTM uses a flow cell to pass particles through a sensing zone one particle at a time and a diode laser to illuminate the particles. The illuminated particles both scatter and absorb a portion of the incident light. Sensors strategically placed around the flow cell collect the scattered light of interest.

An additional sensor placed in the laser path measures the amount of light removed due to light scatter and absorption. This measurement is called Axial Light Loss (Figure 12).

Figure 12. Light Scatter on the DxH 900/DxH 690T Hematology Analyzer



SCATTERPLOT DEVELOPMENT

The System Manager performs a series of operations on the stored digital raw values received from the flow cell to identify populations and calculate the frequency of cells within each population. The system produces the dataplot displays for visual representation of the Differential, NRBC, and Reticulocyte population and density (Table 1; Figures 13 and 14).

The DxH 900/690T analyzer system algorithm uses tools designed for finding optimal separation between overlapping clusters of data.

Dynamic Gating technology can:

- › Adapt to unusual population shifts and overlaps
- › Define highly irregular separation
- › Make subsequent analysis of the identified regions
- › Correct deficiencies in separation

In the dataplots, different colors represent different populations (types of cells). Shades of colors represent density (concentration): dark colors for low density, bright colors for high density.

Table 1. Dataplot Development

Diff Analysis		NRBC Analysis		Retic Analysis	
Lymphocyte	Blue	NRBC	Red	WBC	Blue
Monocyte	Green	Other*	Green	RBC	Red
Neutrophil	Purple	WBC	Blue	PLT/Debris	Green
Eosinophil	Orange			RETIC	Purple
Basophil	White				
Non-White Cell	Red				

*Other includes RBC, PLT, debris



NRBC OPTICAL SCATTER

Sample preparation occurs at the NRBC Diff mix chamber where sample and reagents are added in the following order: Diluent, blood, additional Diluent followed by an air mix. Next, DxH Cell Lyse is added, followed by a second air mix and an incubation period. The prepared sample is transferred to the MTM where cells are counted in an isometric sample stream. The algorithm analysis separates NRBC from WBC (Figure 15).

Figure 13. 3D Scatterplot




Figure 14. 2D Scatterplot

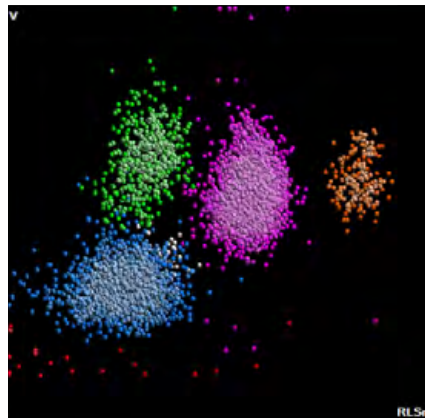
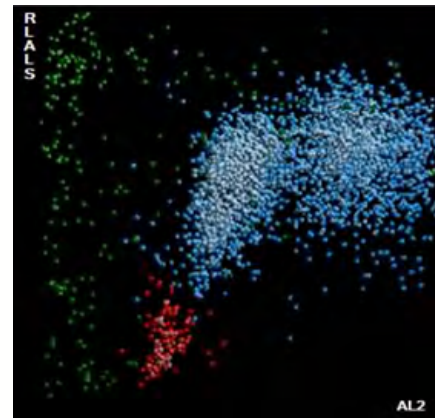


Figure 15. NRBC 2D Scatterplot



RETICULOCYTES

Reticulocytes are immature, non-nucleated erythrocytes retaining a small network of basophilic organelles and contain both RNA and protoporphyrin. The enumeration of reticulocytes provides a simple, effective means to determine red cell production and regeneration. The most common means of measuring reticulocytes is to use supravital dyes such as New Methylene Blue or Brilliant Cresyl Blue. These dyes precipitate and aggregate the basophilic substances within the reticulocytes resulting in a granular staining pattern easily seen with light microscopy.

Reticulocyte immaturity is related to cell volume and light scatter. The cell volume and light scatter increase with the immaturity of the cell since immature reticulocytes are larger, contain more RNA, and cause increased light scatter. Reticulocyte volumes are also measured in the generation of Mean Retic Volume (MRV), a ratio between immature reticulocytes and the total retic population (IRF). The accurate reticulocyte-volume measurement using enhanced digital impedance provides clinical value for specific diseases.

Figure 16. RETIC 2D Dataplot

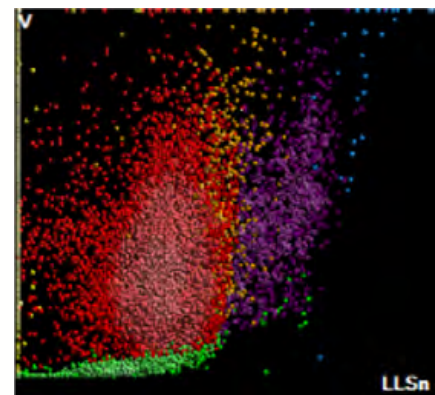
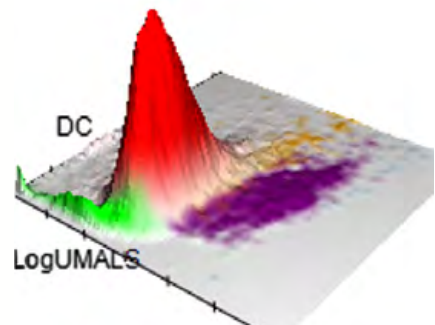


Figure 17. Surface Plot

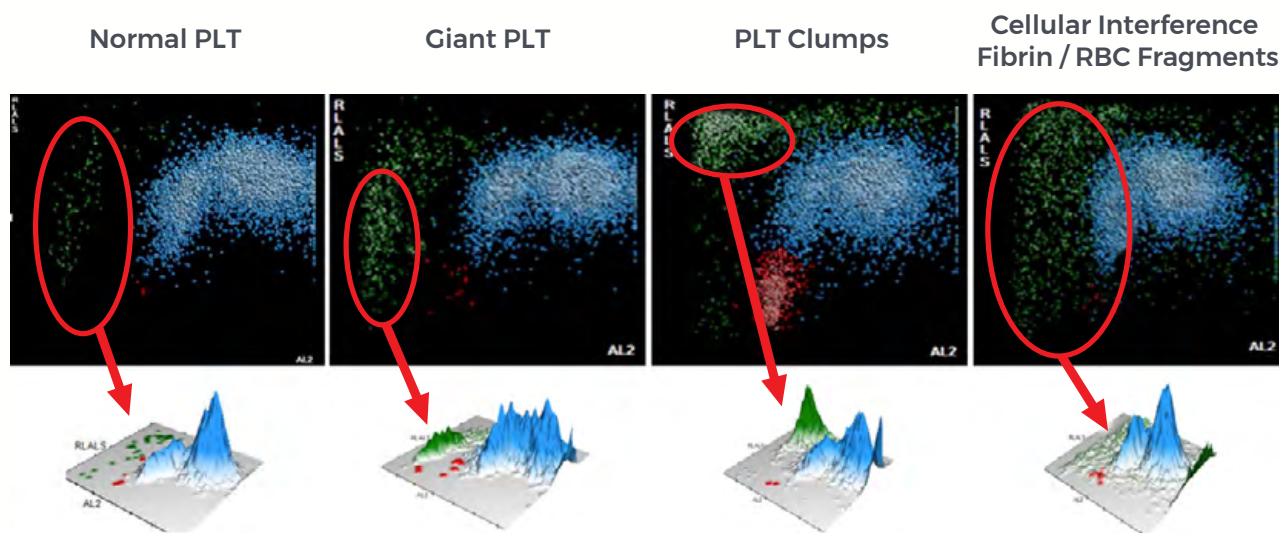




DATAFUSION - INTRA AND EXTRAMODULAR DATA ANALYSIS

DataFusion technology incorporates information from multiple modules—the Enhanced Coulter Principle and VCS—per patient run. The intent of the design is to overcome sample-specific challenges in real time and avoid additional sample blood reanalysis or reruns. DataFusion uniquely incorporates multiple technologies within one run, using the strengths of each module to work together and overcome switching for reanalysis. The DxH platelet count also includes feature information obtained from the WBC histogram and the NRBC analysis. The platelet histogram pattern and the additional feature information from the WBC histogram and NRBC analysis support the PLT count correction due to interferences and PLT R flagging in cases of severe interference (Figure 18)

Figure 18. Data Fusion: Optical Mode Identifying Interferences for Correct Flagging.



EXAMPLE

A giant platelet is a platelet that approximates the size of an average RBC and is typically associated with conditions such as Bernard-Soulier syndrome or other anomalies.

Three separate sources (WBC histogram, extended platelet histogram, and NRBC Data plot) are used to determine the need for flagging (Figure 19). Other interferences can be identified in the optical mode (Figure 18).

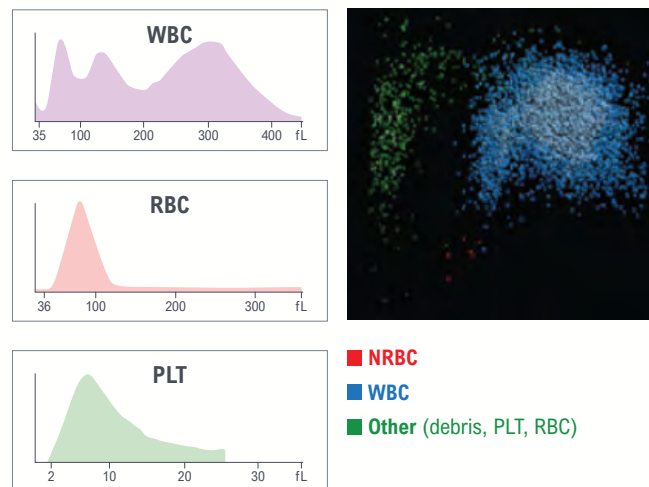


Figure 19. Giant PLT Patterns: CBC Histograms and NRBC Dataplot



Benign Categories

Lymphoid Neoplasms

Myeloid Neoplasms/
Myelodysplastic Syndromes

Red Blood Cell Disorders



1. Cram LS, Arndt-Jovin D, Mack Jett Fulwyler, pioneer of flow cytometry and flow sorting (1936-2001). *Cytometry A*. 2005;67(2):53-54, cover. doi:10.1002/cyto.a.20176
2. Loken MR, Sweet RG, Herzenberg LA. Cell discrimination by multiangle light scattering. *J Histochem Cytochem*. 1976;24(1):284-291. doi:10.1177/24.1.1254923
3. Jovin TM, Morris SJ, Striker G, Schultens HA, Digweed M, Arndt-Jovin DJ. Automatic sizing and separation of particles by ratios of light scattering intensities. *J Histochem Cytochem*. 1976;24(1):269-283. doi:10.1177/24.1.1254922



Benign Categories

Case 1	Infectious Mononucleosis
Case 2	Sjögren's Syndrome
Case 3	Persistent Polyclonal B Cell Lymphocytosis
Case 4	Sepsis



CASE 1 | INFECTIOUS MONONUCLEOSIS

Disease Description

Infectious mononucleosis (IM) is a disease primarily of teens and young adults with most patients developing the disease between 15–24 years of age.¹

The most common causative agent of IM is Epstein-Barr Virus (EBV). Almost all adults worldwide become seropositive for the virus at some point in time in their lives, but >95% acquire it before 35 years of age.^{1,2}

Clinicopathologic Features

Approximately 75% of patients with IM develop typical clinical symptoms characterized by abrupt onset of fever, sore throat, swollen neck due to bilateral posterior cervical lymphadenopathy, pharyngitis, malaise, and muscle aches.³

A subset of patients may develop unusual disease manifestations such as hepatosplenomegaly, nausea, vomiting, palatal petechiae, and skin rash.⁴

Complications can develop from acute illness, although they are rare. These include but are not limited to splenic rupture, chronic active EBV infection, and EBV-associated hemophagocytic syndrome.^{5,6}

In the case of suspected IM, the heterophile antibody test is used as a screening test. The test is relatively fast, inexpensive, and easy to perform. It, however, is not specific and can be positive for other diseases including acute infections, autoimmune diseases, and cancers. Also, false negative results are common in children.⁷⁻⁹ Further, the heterophile test may be falsely negative in approximately a quarter of patients in the first week of acute illness.

EBV-specific antibody tests (antibody testing for viral capsid antigen immunoglobulin M) can be used to confirm the suspected diagnosis of IM in case of a negative heterophile antibody test. A positive antiviral capsid antigen IgM antibody test is diagnostic of IM.^{10,11}

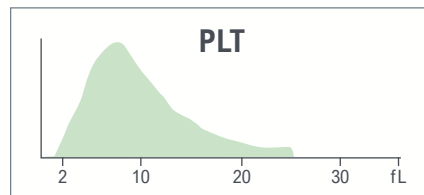
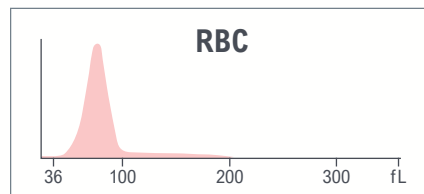
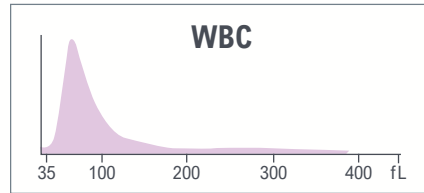
If serologic tests are not helpful (less likely), then molecular analysis by real-time polymerase chain reaction (RT-PCR) and measurement of Epstein-Barr virus viral load can be helpful.¹²

CBC parameters indicate leukocytosis and microcytosis without anemia.

WBC histogram shows predominant population in the lymphocyte region.

Yellow indicates an action limit is exceeded.

Test	Result	Flags
WBC	13.8	H
UWBC	13.8	H
RBC	4.97	
HGB	13.0	
HCT	37.7	
MCV	75.9	
MCH	26.3	
MCHC	34.6	
RDW	14.2	
RDW-SD	38.5	
PLT	202	
MPV	9.3	



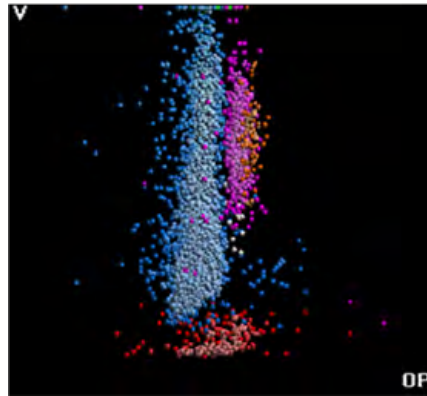
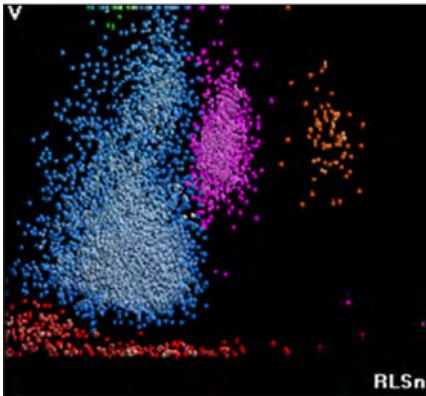
Test	Result	Flags
NE	11.8	L
LY	86.5	H
MO	0.3	L
EO	1.1	
BA	0.3	
NE#	1.6	L
LY#	11.9	aH
MO#	0.0	L
EO#	0.1	
BA#	0.0	
NRBC	0.4	
NRBC#	0.05	H

Results of the WBC automated differential show neutropenia, monocytopenia, and lymphocytosis.





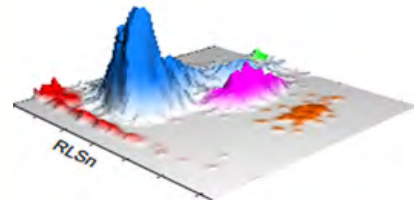
LEUKOCYTES



Suspect messages

- LY Blast
- Variant LY

WBC Analysis 5PD1
3D Surface plot



5PD1 plot (Scatter vs. Volume) and 5PD2 plot (Opacity vs. Volume) show abnormal patterns with predominant lymphocyte population as indicated by instrument messages.

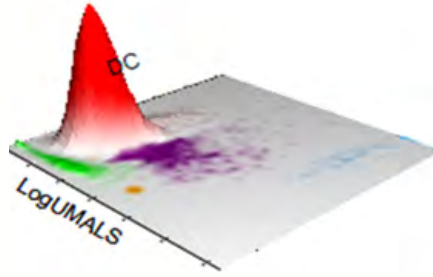

	NE		LY		MO		EO	
	Mean	SD	Mean	SD	Mean	SD	Mean	SD
V	165	24.76 ↑	108 ↑	42.48 ↑	254 ↑	3.65	170	22.13
C	139	7.06	114	8.00	117	5.24	146	3.57
MALS	132	10.51	76	19.34	67	7.89	196	9.78
UMALS	143	10.95	79	21.17	69	17.15	205	9.26
LMALS	117	14.01	67	21.49	61	8.12	185	11.60
LALS	147	37.37	43	19.03	73	24.06	186	46.26
AL2	150	15.71	87	25.62	171	45.92	120	8.82

The values of Cell Population Data show increased @LY Volume Mean, increased @LY Volume SD, increased @MO Volume Mean, and increased @NE Volume SD as compared with normal specimens.

For research use only. Not for use in diagnostic procedures.
@ - Research Use Only (RUO) parameters



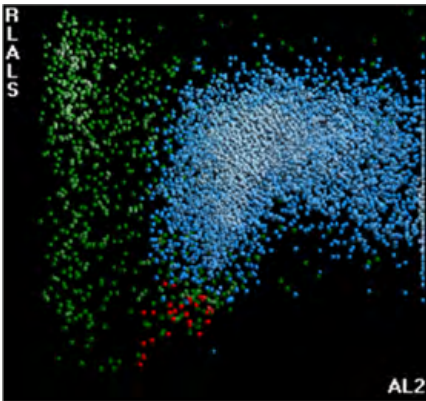
AUTOMATED RETICULOCYTE ANALYSIS



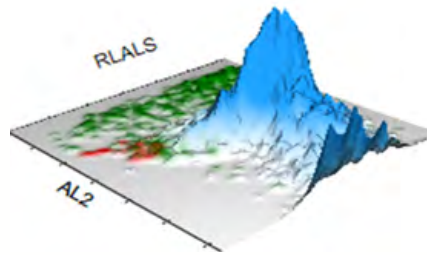
Test	Result	Flags
RET	2.21	
RET#	0.1099	H
MRV	90.7	L
IRF	0.34	

High reticulocyte number and low MRV.

NRBC

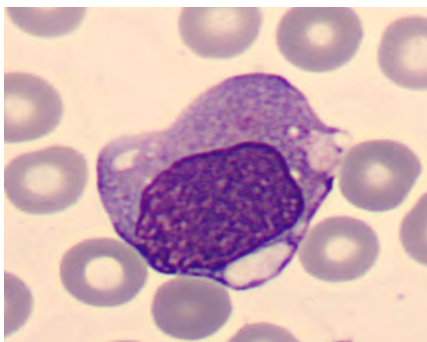
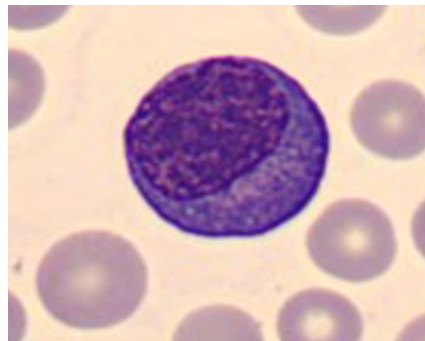
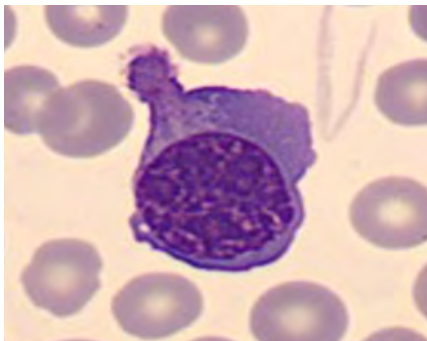
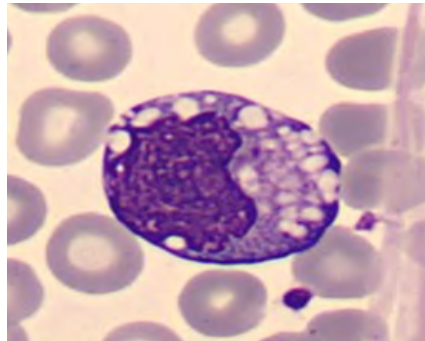
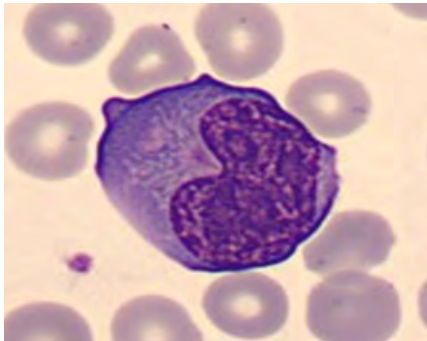
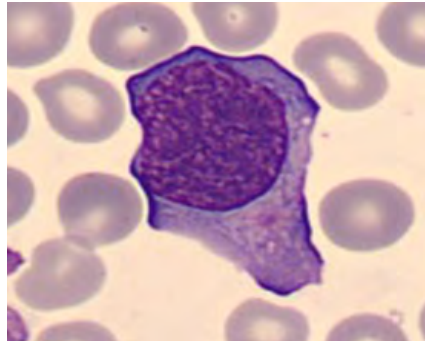
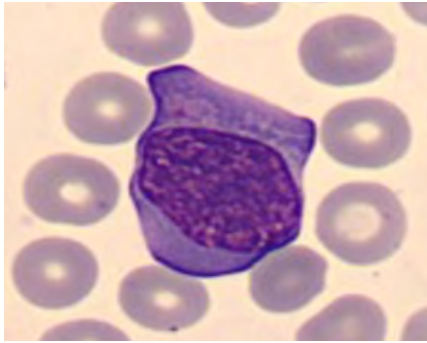


NRBC1 plot shows some NRBCs.





BLOOD SMEAR



Manual Differential	
Neutrophils	9
Band Neutrophils	0
Lymphocytes	53
Monocytes	5
Eosinophils	2
Basophils	0.5
Metamyelocytes	
Myelocytes	
Promyelocytes	
Immature Granulocytes	0
Atypical Lymphocytes	30.5
Blast	0
NRBC	

Summary Results

- › Microcytosis without anemia, high Retics, and low MRV
- › PLT count and PLT histogram are normal
- › Leukocytosis with lymphocytosis, neutropenia, and monocytopenia. WBC histogram shows predominant population in the lymphocyte region
- › 5PD1 plot (Scatter vs. Volume) and 5PD2 plot (Opacity vs. Volume) show macrocytosis and anisocytosis of lymphocytes, macrocytosis of monocytes, and anisocytosis of neutrophils
- › 30.5% of atypical lymphocytes observed on the blood film (83.5% Lymphocytes in total)

DIAGNOSIS: INFECTIOUS MONONUCLEOSIS



CASE 2 | SJÖGREN'S SYNDROME

Disease Description

Sjögren's syndrome (SS) is a chronic systemic autoimmune disease presenting with xerophthalmia (dry eyes) and/or xerostomia (dry mouth). It can occur at any age but is most common in people over the age of 40 at the time of diagnosis. This condition is much more common in women. Many patients develop SS as a complication of another autoimmune disease such as rheumatoid arthritis or systemic lupus erythematosus.

Most patients with SS remain healthy, but some rare complications have been described including an increased risk for cancer of the lymph nodes (lymphoma). Thus, regular medical care and follow-up is important for all patients.

Most of the treatment for SS is aimed at relieving symptoms of dry eyes and mouth and preventing and treating long-term complications such as infection and dental disease.

Clinicopathologic Features

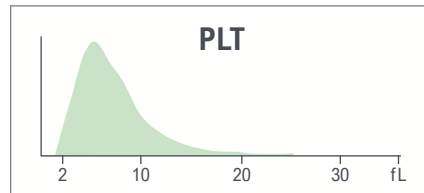
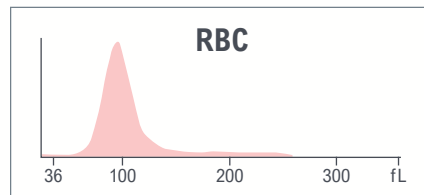
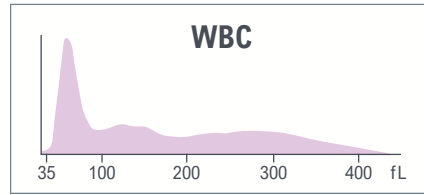
- › Anemia and leukopenia are the most common hematologic manifestations of primary SS, while thrombocytopenia is less common.^{13,14} Autoimmune hemolytic anemia (AIHA) is an uncommon but clinically significant complication of SS
- › Blood tests detect specific antibodies as anti-nuclear antibodies (ANA), anti-SS antibodies (anti-SSA, also called anti-Ro), and anti-SS type B (anti-SS-B, also called anti-La antibodies). A blood test can also detect rheumatoid factor, an antibody found in many people who have rheumatoid arthritis



CBC parameters indicate leukocytosis and thrombocytosis.

Yellow indicates an action limit is exceeded.

Test	Result	Flags
WBC	15.7	H
UWBC	15.7	H
RBC	4.08	
HGB	12.9	
HCT	40.4	
MCV	98.9	H
MCH	31.6	
MCHC	32.0	L
RDW	14.9	
RDW-SD	50.8	H
PLT	503	H
MPV	7.6	



Test	Result	Flags
NE	44.0	
LY	36.3	
MO	11.5	
EO	6.9	
BA	1.3	
NE#	6.9	
LY#	5.7	aH
MO#	1.8	aH
EO#	1.1	aH
BA#	0.2	H
NRBC	0.0	
NRBC#	0.00	

The results of the WBC automated differential indicate lymphocytosis, monocytosis, eosinophilia, and basophilia.

Benign Categories

Lymphoid Neoplasms


Myeloid Neoplasms/
Myelodysplastic Syndromes

Red Blood Cell Disorders

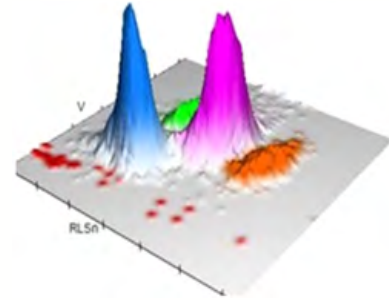




LEUKOCYTES



Suspect messages
 · Left Shift
 WBC Analysis 5PD1
 3D Surface plot



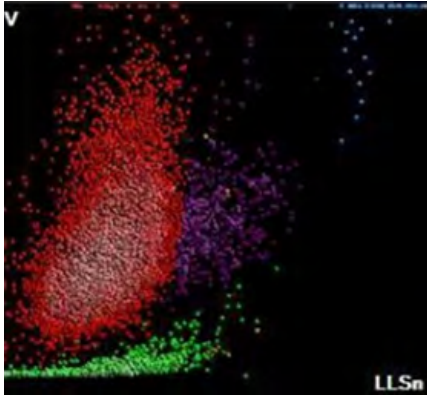
5PD1 plot (Scatter vs. Volume) and 5PD2 plot (Opacity vs. Volume) show presence of large neutrophils as indicated by instrument message.

	NE		LY		MO		EO	
	Mean	SD	Mean	SD	Mean	SD	Mean	SD
V	148	21.20 ↑	90	11.36	160	24.01 ↑	147	20.97
C	153	5.79	128	7.07	134	7.67	159	6.10
MALS	132	11.93	75	15.19	88	12.55	181	10.39
UMALS	134	12.44	77	16.86	103	12.16	198	10.44
LMALS	126	15.93	68	19.18	69	18.25	159	16.39
LALS	179	42.84	39	10.07	67	30.87	161	53.74
AL2	143	12.62	73	7.47	121	11.91	134	11.29

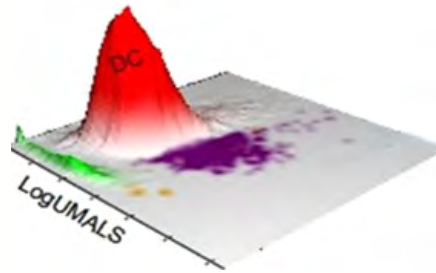
The values of Cell Population Data show increased @NE Volume SD and increased @MO Volume SD as compared with normal specimen.



AUTOMATED RETICULOCYTE ANALYSIS

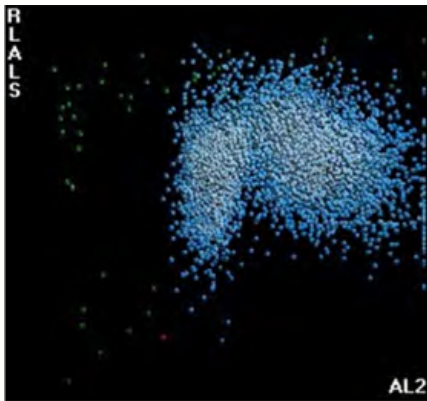


No abnormalities for reticulocytes.

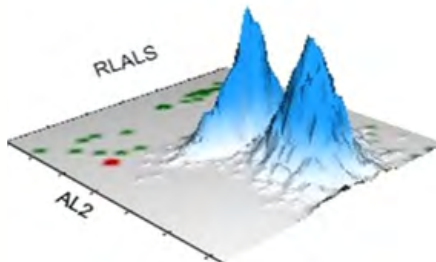


Test	Result	Flags
RET	1.33	
RET#	0.0542	
MRV	117.4	
IRF	0.46	

NRBC

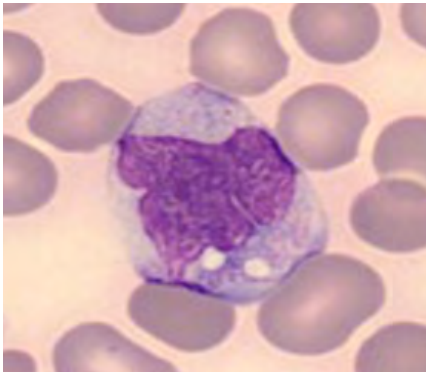
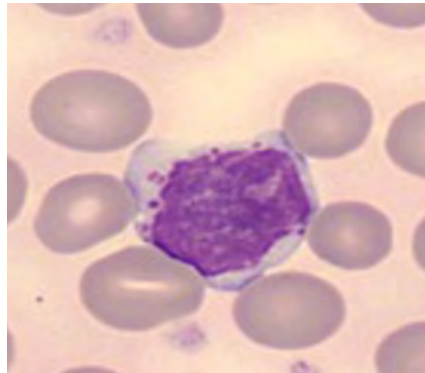
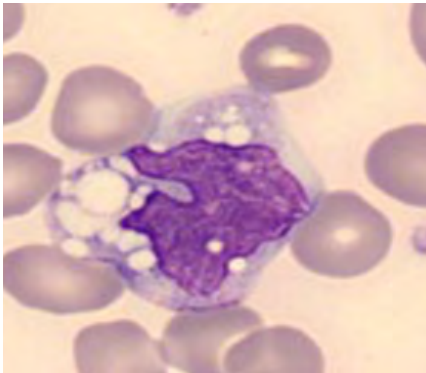
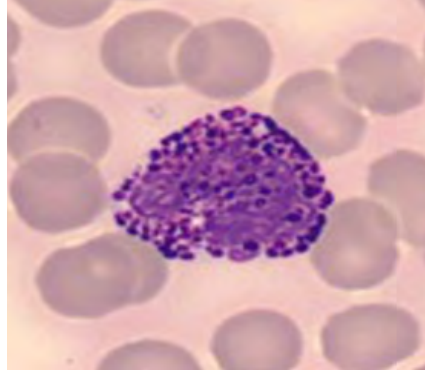
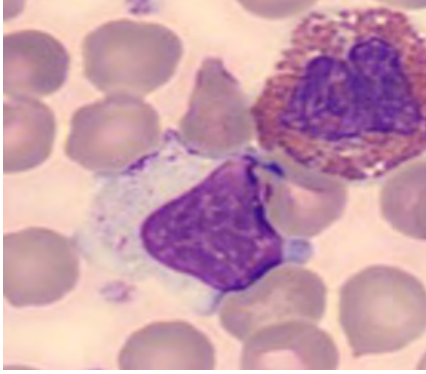


NRBC1 plot does not show any abnormalities.





BLOOD SMEAR



Manual Differential	
Neutrophils	43
Band Neutrophils	0
Lymphocytes	39
Monocytes	10
Eosinophils	2
Basophils	1
Metamyelocytes	
Myelocytes	
Promyelocytes	
Immature Granulocytes	
Atypical Lymphocytes	
Blast	
NRBC	

Comments:

Lymphocytosis prompts evaluation for the exclusion of lymphoproliferative disorder. Flow cytometry on peripheral blood can be performed to assess for B-cell clonality.

Summary Results

- › Leukocytosis with absolute lymphocytosis, monocytosis, eosinophilia, and basophilia
- › 5PD1 plot (Scatter vs. Volume) and 5PD2 plot (Opacity vs. Volume) show anisocytosis of neutrophils and monocytes
- › Thrombocytosis

DIAGNOSIS: SJÖGREN'S SYNDROME



CASE 3 | PERSISTENT POLYCLONAL B CELL LYMPHOCYTOSIS

Disease Description

Persistent polyclonal B-cell lymphocytosis (PPBL) is a rare hematological disorder first described in 1982. It occurs predominantly, but not exclusively, in young to middle-aged (40–50 years) smoking women.¹⁵

It is characterized by persistent absolute and moderate lymphocytosis of more than $4 \times 10^9/L$ with circulating hallmark binucleated lymphocytes and elevated polyclonal serum IgM.

Most patients have a benign clinical course on long-term follow-up. The risk of developing hematologic or non-hematologic malignancy in patients with PPBL is still not well-established. While there are anecdotal reports of lymphoma, monoclonal gammopathy of undetermined significance (MGUS), and lung cancer developing in patients with PPBL, large-scale studies are missing.

Clinicopathologic Features

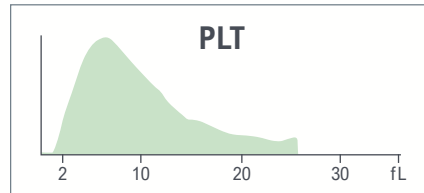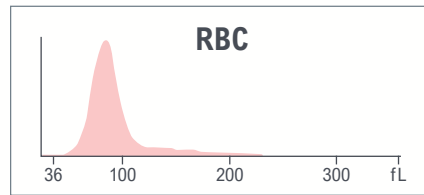
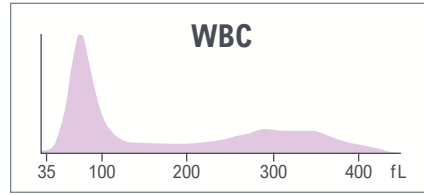
- › Sustained lymphocytosis of more than $4 \times 10^9/L$
- › 10% of lymphocytes binucleated. The remaining lymphocytes are large with an ample amount of cytoplasm, rounded or irregular nuclei with slight indentation, and mature chromatin
- › Polyclonal increase of serum IgM
- › Polyclonal population of CD5-negative B Lymphocytes, normal kappa/lambda ratio
- › Extra isochromosome for the long arm of chromosome 3 +i(3)(q10) is present in up to 70% of cases and G1 premature chromatin condensation can be seen in up to 10% of patients¹⁶



CBC parameters indicate leukocytosis and elevated RBC and Hgb.

Yellow indicates an action limit is exceeded.

Test	Result	Flags
WBC	13.1	H
UWBC	13.1	H
RBC	6.05	aH
HGB	16.7	H
HCT	50.2	H
MCV	82.9	
MCH	27.5	
MCHC	33.2	
RDW	15.2	
RDW-SD	44.2	
PLT	161	
MPV	9.5	



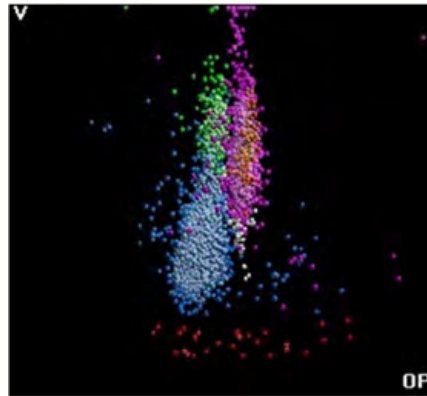

Test	Result	Flags
NE	38.9	L
LY	55.1	H
MO	3.9	L
EO	1.0	
BA	1.1	
NE#	5.1	
LY#	7.2	aH
MO#	0.5	
EO#	0.1	
BA#	0.1	
NRBC	0.2	
NRBC#	0.03	
MDW	16.25	

The results of the WBC automated differential show absolute lymphocytosis.



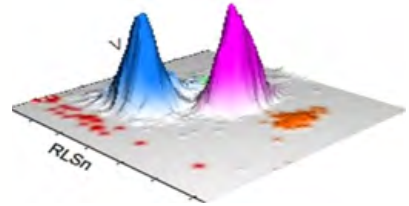


LEUKOCYTES



Suspect messages
 • Variant Lymph

WBC Analysis 5PD1
 3D Surface plot



5PD1 plot (Scatter vs. Volume) and 5PD2 plot (Opacity vs. Volume) show enlarged LY population with some big lymphocytes.

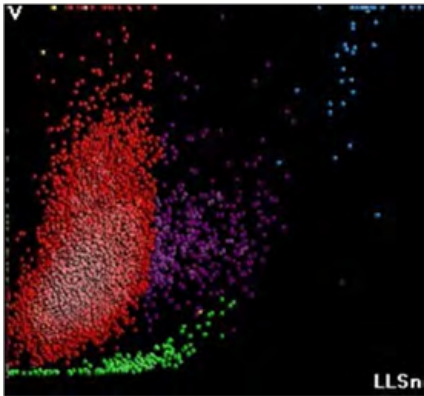
	NE		LY		MO		EO	
	Mean	SD	Mean	SD	Mean	SD	Mean	SD
V	157	20.34	101 ↑	20.95 ↑	178	17.32	163	14.84
C	142	5.38	116	7.91	124	5.54	145	3.32
MALS	135	10.61	76	16.51	94	11.75	200	8.51
UMALS	139	10.88	81	17.79	104	12.09	213	9.59
LMALS	126	13.48	66	19.13	80	13.94	183	9.73
LALS	172	30.17	38	13.41	104	27.45	179	39.42
AL2	147	11.87	83	14.61	141	12.33	132	10.30

The values of Cell Population Data show increased @LY Volume Mean and increased @LY Volume SD as compared with normal specimen.

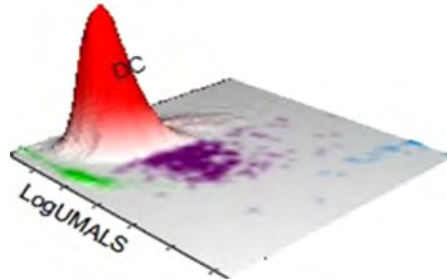




AUTOMATED RETICULOCYTE ANALYSIS

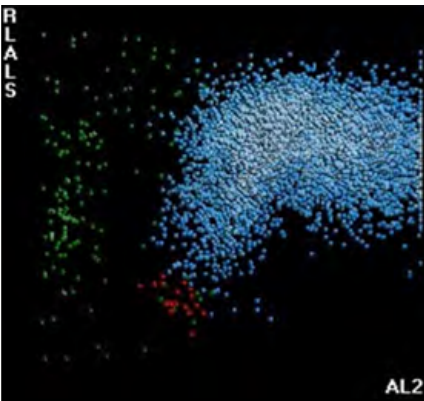


No abnormalities related to reticulocytes.

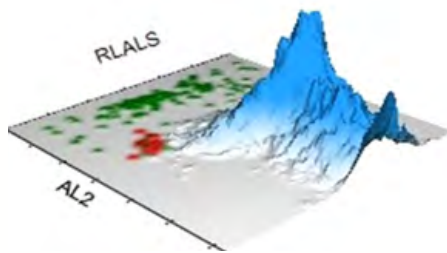


Test	Result	Flags
RET	1.24	
RET#	0.0753	
MRV	102.1	
IRF	0.41	

NRBC

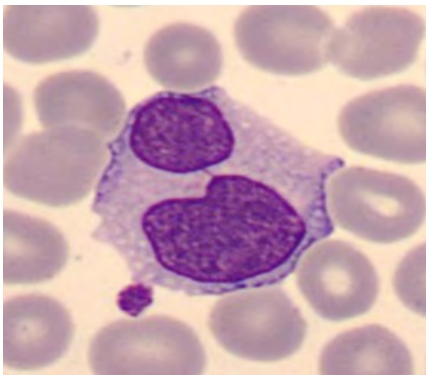
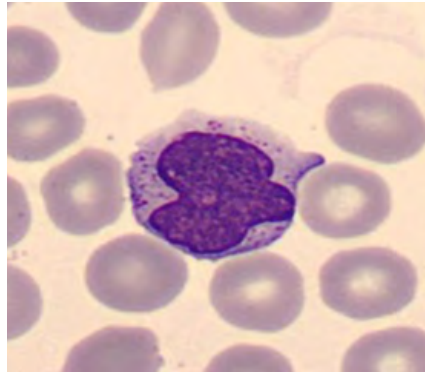
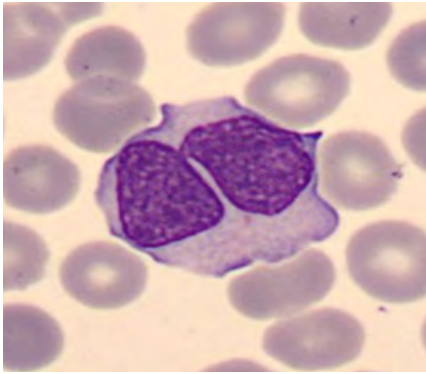


No abnormalities observed on NRBC1 plot.





BLOOD SMEAR



Manual Differential	
Neutrophils	37
Band Neutrophils	0
Lymphocytes	49
Monocytes	12
Eosinophils	1
Basophils	1
Metamyelocytes	
Myelocytes	
Promyelocytes	
Immature Granulocytes	
Atypical Lymphocytes	
Blast	
NRBC	

Summary Results

- › Leukocytosis with absolute lymphocytosis
- › Elevated RBC and Hgb
- › Platelet count and platelet histogram are normal
- › 5PD1 plot (Scatter vs. Volume) and 5PD2 plot (Opacity vs. Volume) show lymphocyte anisocytosis with large volume lymphocytes
- › Marked lymphocytosis with several large reactive lymphocytes suggesting a possible viral infection. Other few binucleated lymphocytes

DIAGNOSIS: PERSISTENT POLYCLONAL B-CELL LYMPHOCYTOSIS



CASE 4 | SEPSIS

Disease Description

Sepsis, a syndrome of physiologic, pathologic, and biochemical abnormalities induced by infection, is a major public health concern. It is estimated that globally there are close to 31 million sepsis cases occurring annually of which approximately 5 million succumb to the condition, thus highlighting the high risk of mortality associated with sepsis.¹⁷

Sepsis is defined by the Third International Consensus (Sepsis-3) as life-threatening organ dysfunction caused by a dysregulated host response to infection.¹⁸

Septic shock is defined by the Third International Consensus as a subset of sepsis in which the risk of mortality is substantially increased and is characterized by hypotension that persists during volume resuscitation and requires the use of vasopressors to maintain a mean arterial blood pressure of >65 mmHg and an increased plasma lactate level of >2 mmol per liter.^{18,19}

Clinicopathologic Features

Sepsis occurs as a result of community or hospital-acquired infections with pneumonia being the most common cause of sepsis followed by intra-abdominal and urinary tract infections.^{20,21}

Sepsis is caused by both Gram-positive and Gram-negative microorganisms. Amongst the organisms responsible for worldwide sepsis cases, *Staphylococcus aureus*, *Streptococcus pneumoniae*, *Escherichia coli*, *Klebsiella* species, and *Pseudomonas aeruginosa* top the list.^{22,23}

Clinical signs and symptoms are heterogeneous and depend on the type of infection, the causative organism, and the number of organs involved as well as the overall health status of the patient. Multiple organs are involved in a typical case of sepsis. Common manifestations include acute respiratory distress syndrome, hypotension requiring the use of vasopressors, elevated lactate dehydrogenase, altered mental status, reduced urine output paralleling increasing blood urea nitrogen and creatinine levels, cytopenias, and coagulation abnormalities.²⁴⁻²⁶

According to the guidelines of the Third International Consensus (Sepsis-3), patients likely to have sepsis are patients with suspected infection or clinically evident infection and ≥ 2 SIRS criteria (a mix of clinical and laboratory criteria) or ≥ 2 qSOFA criteria (Glasgow Coma Scale score of 13 or less, systolic blood pressure of 100 mm Hg or less, and respiratory rate 22/min or greater).¹⁸

LABORATORY FINDINGS²⁵

- › Monocyte Distribution Width (MDW) >20 (when using K2 EDTA) or MDW >21.5 (when using K3 EDTA)
- › WBC count >12000/ μ L or <4000/ μ L or normal WBC count with >10% immature bands
- › Elevated plasma C-reactive protein and procalcitonin more than 2 standard deviations above normal
- › Serum Creatinine >0.5 mg/dL or 44.2 μ mol/L
- › Coagulation abnormalities INR >1.5 or PTT >60 seconds
- › Thrombocytopenia (<100,000/ μ L)
- › Total bilirubin >4 mg/dL

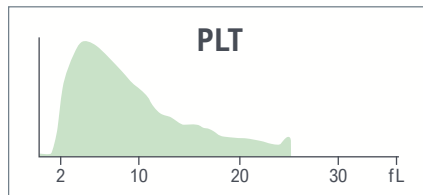
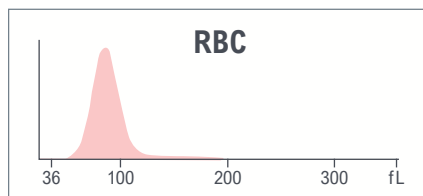
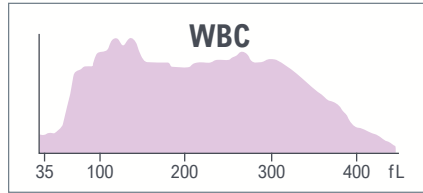


CBC parameters indicate leukopenia, normocytic anemia with anisocytosis, and thrombocytopenia.

Abnormal WBC histogram with elevated area between 100 and 300 fL.

Yellow indicates an action limit is exceeded.

Test	Result	Flags
WBC	2.3	L
UWBC	2.3	L
RBC	2.76	L
HGB	8.5	L
HCT	24.6	L
MCV	88.9	
MCH	30.8	
MCHC	34.7	
RDW	15.1	
RDW-SD	46.4	H
PLT	40	aL
MPV	8.9	



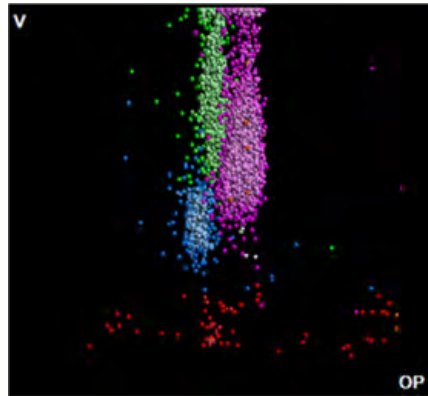

Test	Result	Flags
NE	66.6	
LY	5.7	L
MO	27.4	H
EO	0.1	L
BA	0.2	
NE#	1.5	L
LY#	0.1	L
MO#	0.6	
EO#	0.0	
BA#	0.0	
NRBC	1.1	aH
NRBC#	0.03	
MDW	27.0	

The results of the WBC automated differential show neutropenia and lymphopenia, abnormal MDW 27.

- High NRBC
- Elevated MDW




LEUKOCYTES



- Suspect messages
- Imm Grans
 - Left Shift
 - MO Blast
 - NE Blast

WBC Analysis 5PD1
3D Surface plot

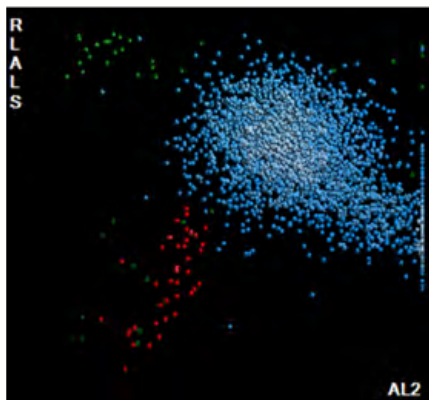


5PD1 plot (Scatter vs. Volume) and 5PD2 plot (Opacity vs. Volume) show abnormal patterns as indicated by instrument messages.

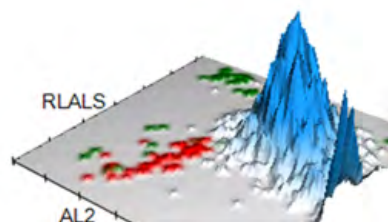
	NE		LY		MO		EO	
	Mean	SD	Mean	SD	Mean	SD	Mean	SD
V	164 ▲	27.31 ▲	115	16.66	192 ▲	25.92 ▲	165	33.61
C	143 ▼	5.58	115	9.56	125	4.76	142	3.92
MALS	124 ▼	13.54	56	17.28	77	13.83	161	4.03
UMALS	126	20.91	57	21.86	84	13.35	170	6.95
LMALS	117	12.50	49	20.68	65	18.11	148	4.12
LALS	143	33.58	45	14.73	80	30.37	115	14.25
AL2	167	17.86	112	11.59	167	14.64	168	13.79

The values of Cell Population Data show increased @NE Volume Mean, @NE Volume SD, @MO Volume Mean, and @MO Volume SD and decreased @NE Conductivity Mean and @NE Scatter Mean as compared with normal specimens.

NRBC

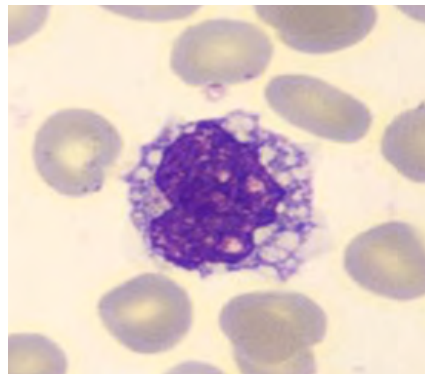
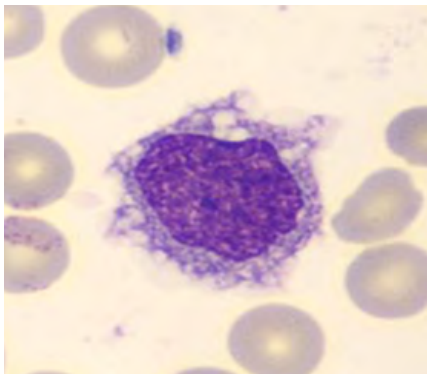
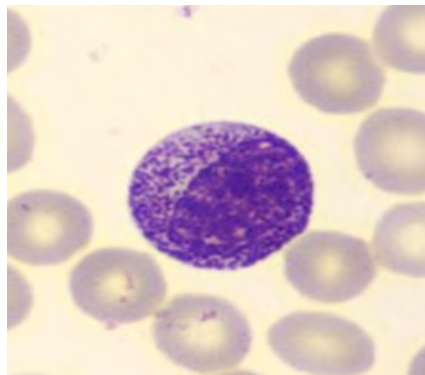
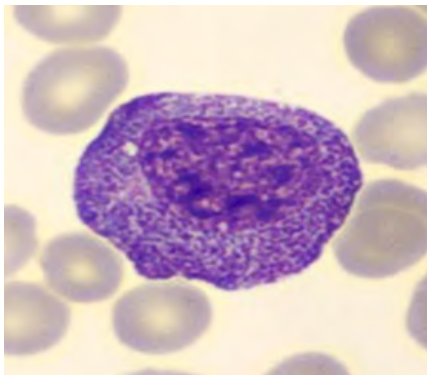
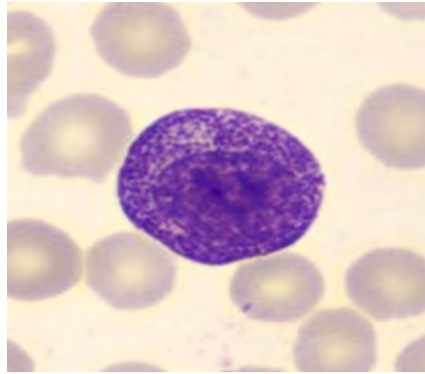
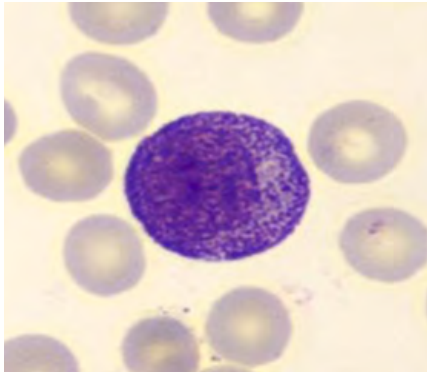


NRBC1 plot shows some NRBC (1.12%).



For research use only. Not for use in diagnostic procedures.
@ - Research Use Only (RUO) parameters

BLOOD SMEAR



Manual Differential	
Neutrophils	40
Band Neutrophils	
Lymphocytes	7
Monocytes	29
Eosinophils	0
Basophils	0
Metamyelocytes	
Myelocytes	
Promyelocytes	
Immature Granulocytes	24
Atypical Lymphocytes	
Blast	
NRBC	

Summary Results

- › Normocytic anemia with anisocytosis
- › Thrombocytopenia
- › Leukopenia with neutropenia and lymphopenia, abnormal MDW. High NRBC
- › Macrocytosis and anisocytosis of neutrophils and monocytes
- › 24% of immature grans observed on the blood film

DIAGNOSIS: SEPSIS



- Luzuriaga K, Sullivan JL. Infectious mononucleosis. *N Engl J Med*. 2010;362(21):1993-2000. doi:10.1056/NEJMc1001116.
- Womack J, Jimenez M. Common questions about infectious mononucleosis. *Am Fam Physician*. 2015;91(6):372-376.
- Balfour HH, Odumade OA, Schmeling DO, et al. Behavioral, virologic, and immunologic factors associated with acquisition and severity of primary Epstein-Barr virus infection in university students. *J Infect Dis*. 2013;207(1):80-88. doi:10.1093/infdis/jis646.
- Dunmire SK, Hogquist KA, Balfour HH. Infectious Mononucleosis. *Curr Top Microbiol Immunol*. 2015;390(Pt 1):211-240. doi:10.1007/978-3-319-22822-8_9.
- Jordan MB, Allen CE, Weitzman S, Filipovich AH, McClain KL. How I treat hemophagocytic lymphohistiocytosis. *Blood*. 2011;118(15):4041-4052. doi:10.1182/blood-2011-03-278127.
- Putukian M, O'Connor FG, Stricker P, et al. Mononucleosis and athletic participation: an evidence-based subject review. *Clin J Sport Med*. 2008;18(4):309-315. doi:10.1097/JSM.0b013e31817e34f8.
- Phillips GM. False-positive monospot test result in rubella. *JAMA*. 1972;222(5):585. doi:10.1001/jama.1972.03210050057025.
- Sadoff L. False-Positive Infectious Mononucleosis Spot Test in Pancreatic Carcinoma. *JAMA*. 1971;218(8):1297. doi:10.1001/jama.1971.03190210151022.
- Fisher BAC, Bhalara S. False-positive result provided by rapid heterophile antibody test in a case of acute infection with hepatitis E virus. *J Clin Microbiol*. 2004;42(9):4411. doi:10.1128/JCM.42.9.4411.2004.
- Hurt C, Tammaro D. Diagnostic evaluation of mononucleosis-like illnesses. *Am J Med*. 2007;120(10):911.e1-8. doi:10.1016/j.amjmed.2006.12.011.
- Hoagland RJ. Infectious mononucleosis. *Prim Care*. 1975;2(2):295-307.
- Vouloumanou EK, Rafailidis PI, Falagas ME. Current diagnosis and management of infectious mononucleosis. *Curr Opin Hematol*. 2012;19(1):14-20. doi:10.1097/MOH.0b013e32834daa08.
- Schattner A, Friedman J, Klepfish A, Berrebi A. Immune cytopenias as the presenting finding in primary Sjögren's syndrome. *QJM*. 2000;93(12):825-829. doi:10.1093/qjmed/93.12.825.
- Aoki A, Ohno S, Ueda A, et al. [Hematological abnormalities of primary Sjogren's syndrome]. *Nihon Rinsho Meneki Gakkai Kaishi*. 2000;23(2):124-128. doi:10.2177/jsci.23.124.
- Gordon DS, Jones BM, Browning SW, Spira TJ, Lawrence DN. Persistent polyclonal lymphocytosis of B lymphocytes. *N Engl J Med*. 1982;307(4):232-236. doi:10.1056/NEJM198207223070407.
- Troussard X, Cornet E, Lesesve J-F, Kourel C, Mossafa H. Polyclonal B-cell lymphocytosis with binucleated lymphocytes (PPBL). *Onco Targets Ther*. 2008;1:59-66. doi:10.2147/ott.s4182.
- Fleischmann C, Scherag A, Adhikari NKJ, et al. Assessment of Global Incidence and Mortality of Hospital-treated Sepsis. Current Estimates and Limitations. *Am J Respir Crit Care Med*. 2016;193(5):259-272. doi:10.1164/rccm.201504-0781OC.
- Singer M, Deutschman CS, Seymour CW, et al. The Third International Consensus Definitions for Sepsis and Septic Shock (Sepsis-3). *JAMA*. 2016;315(8):801-810. doi:10.1001/jama.2016.0287.
- Hotchkiss RS, Moldawer LL, Opal SM, Reinhart K, Turnbull IR, Vincent J-L. Sepsis and septic shock. *Nat Rev Dis Primers*. 2016;2:16045. doi:10.1038/nrdp.2016.45.
- Vincent J-L, Rello J, Marshall J, et al. International study of the prevalence and outcomes of infection in intensive care units. *JAMA*. 2009;302(21):2323-2329. doi:10.1001/jama.2009.1754.
- Angus DC, Linde-Zwirble WT, Lidicker J, Clermont G, Carcillo J, Pinsky MR. Epidemiology of severe sepsis in the United States: analysis of incidence, outcome, and associated costs of care. *Crit Care Med*. 2001;29(7):1303-1310. doi:10.1097/00003246-200107000-00002.
- Ranieri VM, Thompson BT, Barie PS, et al. Drotrecogin alfa (activated) in adults with septic shock. *N Engl J Med*. 2012;366(22):2055-2064. doi:10.1056/NEJMoa1202290.
- Opal SM, Garber GE, LaRosa SP, et al. Systemic host responses in severe sepsis analyzed by causative microorganism and treatment effects of drotrecogin alfa (activated). *Clin Infect Dis*. 2003;37(1):50-58. doi:10.1086/375593.
- ARDS Definition Task Force, Ranieri VM, Rubenfeld GD, et al. Acute respiratory distress syndrome: the Berlin Definition. *JAMA*. 2012;307(23):2526-2533. doi:10.1001/jama.2012.5669.
- Dellinger RP, Levy MM, Rhodes A, et al. Surviving sepsis campaign: international guidelines for management of severe sepsis and septic shock: 2012. *Crit Care Med*. 2013;41(2):580-637. doi:10.1097/CCM.0b013e31827e83af.
- De Jonghe B, Sharshar T, Lefaucheur J-P, et al. Paresis acquired in the intensive care unit: a prospective multicenter study. *JAMA*. 2002;288(22):2859-2867. doi:10.1001/jama.288.22.2859.



Lymphoid Neoplasms

Case 1	Chronic Lymphocytic Leukemia
Case 2	Mantle Cell Lymphoma
Case 3	Hairy Cell Leukemia
Case 4	Adult T- Cell Lymphoma
Case 5	Sézary Syndrome
Case 6	T-Cell Lymphoblastic Leukemia/Lymphoma



CASE 1 | CHRONIC LYMPHOCYTIC LEUKEMIA (CLL)

Disease Description

Chronic Lymphocytic Leukemia (CLL) is a cancer of the blood and bone marrow that develops from a type of white blood cell called B cells. It progresses slowly and usually affects older adults. Over 80% of cases in Western populations are diagnosed from a routine blood analysis in asymptomatic patients. Enlargement of cervical, axillary, or inguinal lymph nodes is observed in about 10–20% of cases. In such cases, small lymphocytic lymphoma (SLL) is the appropriate diagnostic term when the circulating clonal B lymphocyte count is $<5 \times 10^9/L$.

Other manifestations of CLL can include autoimmune cytopenia (thrombocytopenia, autoimmune hemolytic anemia), pulmonary infection, and hypogammaglobulinemia. B-symptoms such as fever, unintentional weight loss, night sweats, and fatigue are seen in approximately 10% of patients.¹

Hepatosplenomegaly is common in CLL/SLL, with splenomegaly more common than hepatomegaly.² CLL may persist for years without causing any symptoms. When symptoms do occur, they may include swollen lymph nodes, fatigue, easy bruising, and skin infiltration in form of papules, macules, plaques, or nodules.³

Treatment isn't always initially necessary but may include chemotherapy. Stem-cell transplant is used in rare scenarios for aggressive cases.

Clinicopathologic Features⁴

CLL cells are a population of monotonous, small lymphocytes with rounded nuclei, smooth nuclear contours, and clumped chromatin, described as 'soccer-ball' or 'cracked earth' chromatin.

In a typical CLL case, nucleoli are not visible.

Other types of cells such as smudge cells or basket cells and a variable proportion of prolymphocytes (medium-sized cells, twice the size of normal lymphocyte with oval-to-rounded nucleus, a single prominent nucleolus, and scant basophilic cytoplasm) are often present in typical CLL.

Cases designated as 'atypical CLL' contain a variable proportion of CLL cells that exhibit more nuclear irregularities or clefted nuclei and small nucleoli.

Prolymphocytes, when present, are always less than 15% of all lymphoid cells. When the proportion of prolymphocytes is greater than 15% but less than 55%, such cases are designated as 'atypical CLL.' It is noteworthy that while the term 'prolymphocytoid transformation' of CLL can be used for cases with increased prolymphocytes, progression of CLL to B-prolymphocytic leukemia does NOT occur.

The diagnosis of CLL is typically established using additional testing and studies, which may include but are not limited to flow cytometry, immunohistochemistry, biopsy analysis, and additional molecular studies.



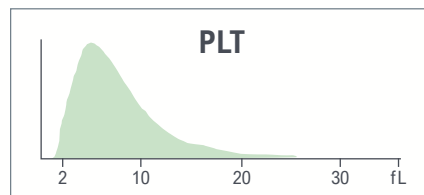
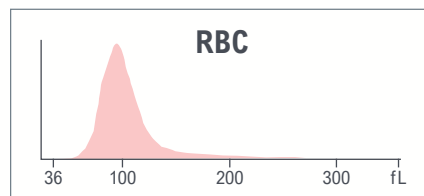
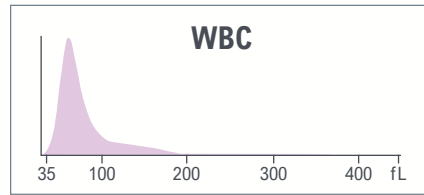
CBC parameters indicate leukocytosis and macrocytosis with anisocytosis without anemia.

WBC histogram shows a predominant population of lymphoid cells.

Red indicates a critical limit is exceeded.

Yellow indicates an action limit is exceeded.

Test	Result	Flags
WBC	70.9	cH
UWBC	70.9	cH
RBC	3.84	L
HGB	13.0	
HCT	39.3	
MCV	102.4	aH
MCH	33.8	H
MCHC	33.0	
RDW	16.0	H
RDW-SD	56.9	H
PLT	159	
MPV	7.9	





Test	Result	Flags
NE	6.6	L
LY	91.4	H
MO	1.3	L
EO	0.5	L
BA	0.2	
NE#	4.7	
LY#	64.9	aH
MO#	0.9	
EO#	0.3	
BA#	0.1	
NRBC	0.0	
NRBC#	0.03	

The results of the WBC automated differential show lymphocytosis.

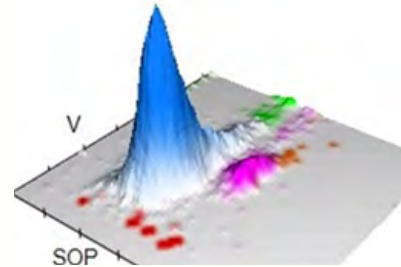


LEUKOCYTES



Suspect messages
· Variant LY

WBC Analysis 5PD1
3D Surface plot




5PD1 plot (Scatter vs. Volume) and 5PD2 plot (Opacity vs. Volume) show abnormal patterns with predominant Ly population as indicated by the instrument messages.

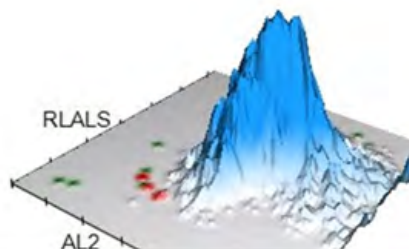
	NE		LY		MO		EO	
	Mean	SD	Mean	SD	Mean	SD	Mean	SD
V	148	32.59 ↑	100 ↑	26.42 ↑	232 ↑	19.01	168	29.81
C	141	6.64	118	6.29	118	21.57	147	3.55
MALS	127	13.87	74	14.36	80	15.38	197	13.98
UMALS	122	16.57	73	16.09	81	18.42	208	14.92
LMALS	124	14.53	68	17.45	74	15.39	182	14.72
LALS	173	40.47	38	17.29	72	37.83	198	43.56
AL2	118	17.35	62	14.92	97	29.99	106	12.52

The values of Cell Population Data show increased @NE Volume SD, increased @LY Volume Mean, increased @LY Volume SD and increased @MO Volume Mean as compared with normal specimen.

NRBC



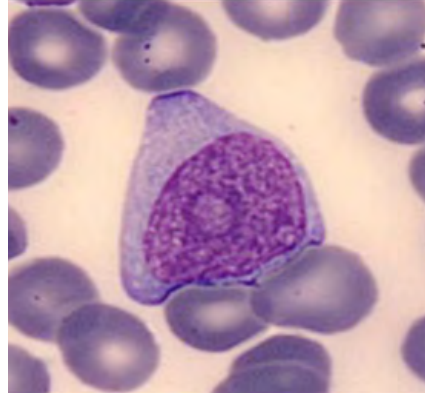
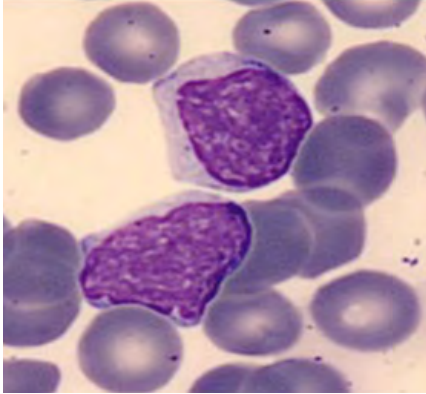
NRBC1 plot shows large Ly population, no NRBC



For research use only. Not for use in diagnostic procedures.
@ - Research Use Only (RUO) parameters



BLOOD SMEAR



Manual Differential	
Neutrophils	6
Band Neutrophils	0
Lymphocytes	92
Monocytes	1.5
Eosinophils	0
Basophils	
Metamyelocytes	
Myelocytes	
Promyelocytes	
Immature Granulocytes	0
Atypical Lymphocytes	
Blast	
NRBC	

Summary Results

- > Leukocytosis with lymphocytosis, abnormal WBC histogram with predominant Ly population
- > Macrocytosis and anisocytosis without anemia
- > Normal PLT count with normal MPV
- > 5PD1 plot (Scatter vs. Volume) and 5PD2 plot (Opacity vs. Volume) show abnormal patterns with big volume lymphocytes and Ly anisocytosis, neutrophil anisocytosis, and monocyte macrocytosis
- > Majority of cells on the slide are lymphocytes, some with the morphology of prolymphocytes

DIAGNOSIS: CHRONIC LYMPHOCYTIC LEUKEMIA (CLL)



CASE 2 | MANTLE CELL LYMPHOMA

Disease Description

Mantle cell lymphoma (MCL) is a mature B-cell neoplasm and comprises 3-10% of non-Hodgkin lymphomas. Males are typically middle-aged or older and affected twice as frequently as females.

MCL diagnosis is established by a combination of flow cytometric immunophenotyping and immunohistochemical analysis performed on tissue biopsy (often an involved lymph node) and/or bone marrow biopsy.

Clinicopathologic Features⁴

Lymph node involvement is most frequent at presentation; however, liver, spleen, and bone marrow involvement are common as well.

Other sites often involved include the gastrointestinal tract, Waldeyer ring, lung, and pleura. Intestinal involvement can sometimes present as multiple intestinal lymphomatous polyposis.

Peripheral blood involvement is almost always seen. Some patients may show marked lymphocytosis in addition to the above modes of presentation. In others, the detection of peripheral blood involvement may not be as obvious without the aid of flow cytometric immunophenotypic analysis.

The diagnosis of MCL is typically established using additional testing and studies, which may include but are not limited to flow cytometry, immunohistochemistry, biopsy analysis, and additional molecular studies

LABORATORY FINDINGS

It is common to see anemia and thrombocytopenia secondary to bone marrow involvement. Lymphocytosis can be seen with an absolute lymphocyte count of $>4000/\mu\text{L}$ in approximately 20-40% cases. Serum LDH and beta-2 microglobulin levels are often elevated. Liver involvement leads to abnormalities in liver function tests.

Mantle cell lymphoma cells in circulation are typically small to medium cells with scant cytoplasm, nuclear irregularities, and reticular chromatin. If the lymphoma cells are medium to large cells with a high nuclear-to-cytoplasmic ratio and fine dispersed chromatin and small or inconspicuous nucleoli resembling acute leukemia, it usually is the blastoid variant of mantle cell lymphoma in circulation. Pleomorphic variant MCL in the leukemic phase typically shows large atypical cells with prominent nucleoli and is often confused with diffuse large B-cell lymphoma cells.

The diagnosis of MCL is typically established using additional testing and studies, which may include but are not limited to flow cytometry, immunohistochemistry, biopsy analysis, and additional molecular studies.

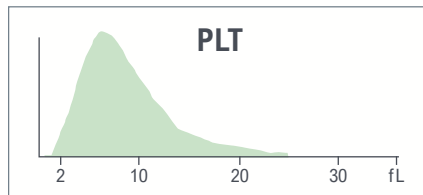
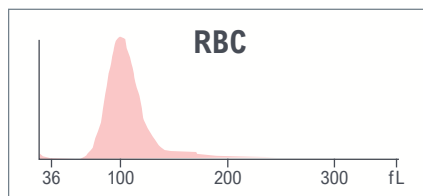
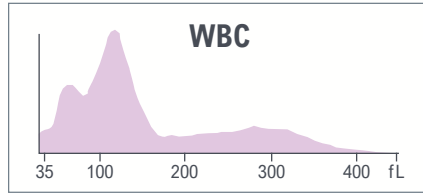
Mantle cell lymphoma diagnosis is established using cytogenetic and/or molecular studies that demonstrate the presence of the characteristic translocation $t(11;14)(q13;q32)$.

CBC parameters indicate macrocytic anemia with slight anisocytosis.

WBC histogram shows abnormal pattern with multiple sub-populations in the area of lymphoid cells.

Yellow indicates an action limit is exceeded.

Test	Result	Flags
WBC	10.0	
UWBC	10.0	
RBC	2.67	L
HGB	9.2	L
HCT	28.9	L
MCV	108.2	aH
MCH	34.4	aH
MCHC	31.8	L
RDW	14.6	
RDW-SD	53.4	H
PLT	260	
MPV	9.6	



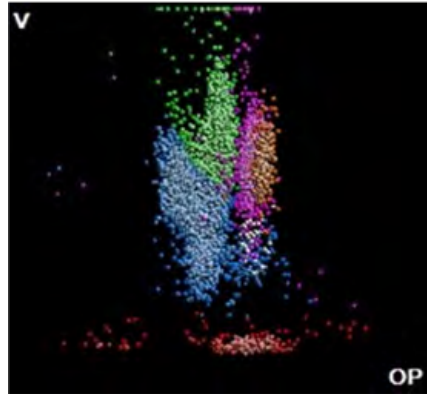

Test	Result	Flags
NE	27.9	L
LY	42.4	
MO	25.4	
EO	3.4	
BA	0.9	
NE#	2.8	
LY#	4.2	H
MO#	2.5	aH
EO#	0.3	
BA#	0.1	
NRBC	1.7	aH
NRBC#	0.17	aH

The results of the WBC automated differential show lymphocytosis, monocytosis, and high NRBC.





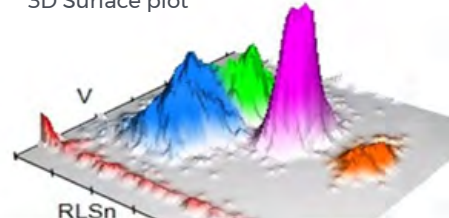
LEUKOCYTES



Suspect messages

- LY Blast
- Variant LY

WBC Analysis 5PD1
3D Surface plot

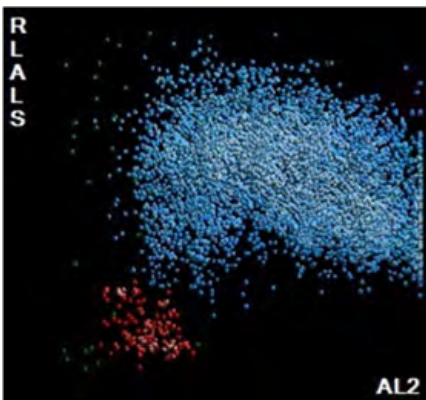


5PD1 plot (Scatter vs. Volume) and 5PD2 plot (Opacity vs. Volume) show abnormal patterns with multiple LY sub-populations

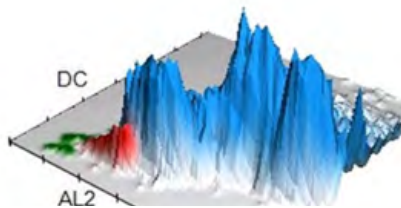
	NE		LY		MO		EO	
	Mean	SD	Mean	SD	Mean	SD	Mean	SD
V	154	18.54	116 ↑	23.81 ↑	170	20.83	153	15.16
C	148	5.58	114	12.91	126	6.84	154	3.70
MALS	144	10.48	64	18.88	82	15.12	207	8.85
UMALS	144	10.99	67	21.48	93	16.06	219	9.64
LMALS	138	12.5	54	21.48	67	18.64	191	9.86
LALS	202	31.11	50	16.72 ↑	94	33.01	186	47.28
AL2	123	12.40	72	16.49 ↑	102	15.18	107	10.42

The values of Cell Population Data show increased @LY Volume Mean, increased @LY Volume SD, increased @LY LALS SD, and increased @LY AL2 SD as compared with normal specimen.

NRBC



NRBC1 plot shows large Ly population, high NRBC

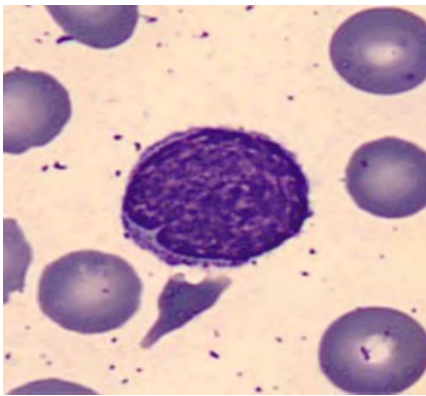
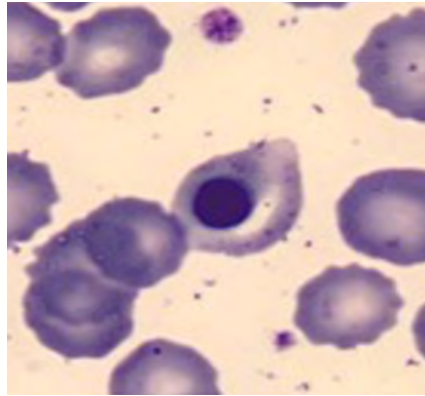
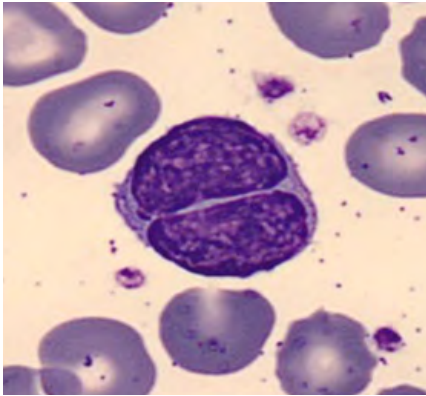


For research use only. Not for use in diagnostic procedures.

@ - Research Use Only (RUO) parameters



BLOOD SMEAR



Manual Differential	
Neutrophils	29
Band Neutrophils	0
Lymphocytes	50
Monocytes	16
Eosinophils	4
Basophils	1
Metamyelocytes	
Myelocytes	
Promyelocytes	
Immature Granulocytes	0
Atypical Lymphocytes	
Blast	
NRBC	

Summary Results

- › Normal WBC count with lymphocytosis, monocytosis, and high NRBC
- › Macrocytic anemia with slight anisocytosis
- › PLT count and PLT histogram are normal
- › WBC histogram shows abnormal pattern with multiple sub-populations in the area of lymphoid cells
- › 5PD1 plot (Scatter vs. Volume) and 5PD2 plot (Opacity vs. Volume) show abnormal pattern, anisocytosis and macrocytosis of lymphocytes and presence of multiple LY sub-populations, which is also indicated by instrument messages
- › Abnormal lymphocytes are observed on blood film: small to medium sized lymphocytes with slightly to markedly irregular nuclear contours, most closely resembling centrocytes
- › Conventional mantle cell lymphoma is seen in 70-80% of patients and presents as symptomatic bulky nodal and extranodal disease. In these patients, it is common to see anemia and thrombocytopenia secondary to bone marrow involvement
- › Lymphocytosis can be seen with an absolute lymphocyte count of >4000/μL in approximately 20-40% of cases
- › Serum LDH and beta-2 microglobulin levels are often elevated
- › Liver involvement leads to abnormalities in liver function tests

DIAGNOSIS: MANTLE CELL LYMPHOMA



CASE 3 | HAIRY CELL LEUKEMIA

Disease Description

Hairy cell leukemia (HCL) is an uncommon B-cell lymphoid neoplasm, accounting for 2 percent of all leukemias.⁵ It is a disease primarily in middle-aged to elderly individuals with a peak incidence between 55–60 years and a median age of 58 years. HCL is more common in men than in women with a male: female ratio of 4:1. Those of European ancestry are more frequently affected than those of African or Asian ancestry.⁶

Clinicopathologic Features⁴

Fatigue and weakness are common at the time of initial presentation. Patients also (in more than 90% of cases) present with left lower quadrant fullness due to massive splenomegaly; however, in recent times, this finding is becoming less common due to earlier detection of the disease.

Recurrent opportunistic infections and hepatomegaly are some other common manifestations found in HCL. Skeletal involvement, autoimmune manifestations, and bleeding diatheses are some uncommon features.

Incidental pancytopenia is the most common presentation at diagnosis, and monocytopenia is a characteristic finding in symptomatic patients with HCL.

The hairy cells have characteristic morphologic features on peripheral smears. Careful evaluation of peripheral blood smears is required as they can often be rare. In the case of typical hairy cell leukemia, hairy cells are medium in size with moderately abundant pale blue cytoplasm, kidney-shaped nuclei, open chromatin, absent nucleoli, and characteristic circumferential fine cytoplasmic projections (hair). The hairy cells impart a ‘fried-egg’ appearance due to their widely spaced nuclei, prominent cell borders, and monotonous oval dark nuclei.

Hairy cell leukemia frequently involves and is best diagnosed in the bone marrow, where hairy cell infiltrates are characteristically interstitial in distribution and are not easy to detect by mere evaluation of histologic sections.

Hairy cells have a characteristic immunophenotype by flow cytometry, which is critical for diagnosis. They frequently show bright expression of CD20, CD22, and CD11c. In addition, they also co-express CD25, CD103, CD123, and CD200. Immunohistochemical staining for CD20 is often required for highlighting hairy cells, which often reveals a more extensive involvement of marrow than is visible on histologic examination.

A combination of CD20, annexin-1, and VE1 (a BRAFV600E stain) immunohistochemistry can help establish the diagnosis and allows for accurate assessment of the degree of bone marrow infiltration by leukemic cells.⁷

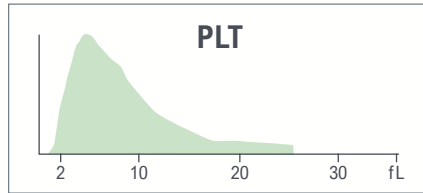
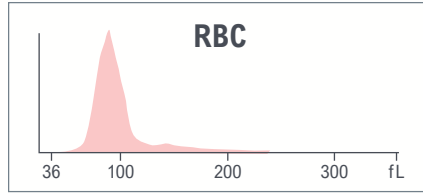
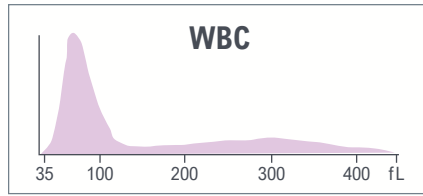
VE1 and TBX21 immunostains are useful in the recognition of residual disease. VE1 can serve as a surrogate for the detection of the BRAFV600E mutation, which is found at a high frequency and has been implicated in the pathogenesis of HCL.

Detection of BRAFV600E also has therapeutic significance, especially in patients who are resistant to standard therapies.⁸ As such, it is recommended that all patients with suspected HCL be assessed for BRAFV600E mutation by allele-specific polymerase chain reaction or next-generation sequencing.

CBC parameters indicate thrombocytopenia and slightly hypochromic normocytic anemia.

WBC histogram shows the predominant LY population.

Test	Result	Flags
WBC	7.3	
UWBC	7.3	
RBC	4.19	
HGB	12.4	L
HCT	38.3	
MCV	01.4	
MCH	29.5	
MCHC	32.3	L
RDW	13.2	
RDW-SD	41.6	
PLT	95	L
MPV	8.4	



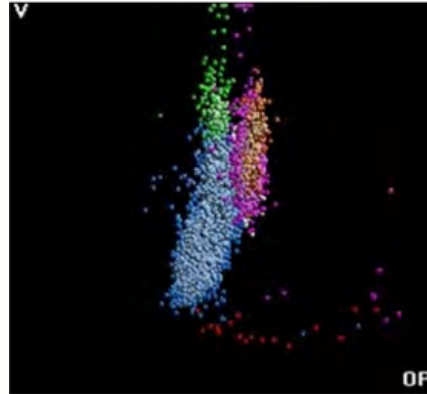

Test	Result	Flags
NE	26.5	L
LY	68.2	H
MO	2.3	L
EO	2.2	
BA	0.8	
NE#	1.9	
LY#	5.0	H
MO#	0.2	L
EO#	0.2	
BA#	0.1	
NRBC	0.3	
NRBC#	0.02	
MDW	0.02	

The results of the WBC automated differential show lymphocytosis and monocytopenia.



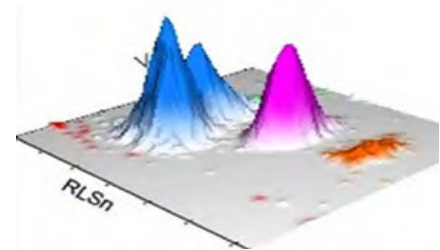


LEUKOCYTES



Suspect messages
• Variant LY

WBC Analysis 5PD1
3D Surface plot

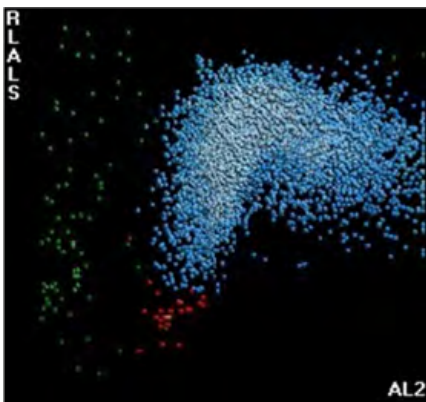


5PD1 plot (Scatter vs. Volume) and 5PD2 plot (Opacity vs. Volume) show abnormal lymphocyte population as indicated by the instrument message.

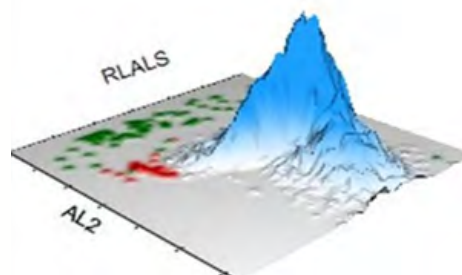
	NE		LY		MO		EO	
	Mean	SD	Mean	SD	Mean	SD	Mean	SD
V	152	18.21	108 ↑	25.66 ↑	190	17.23	166	17.72
C	146	5.47	120	8.56	124	5.22	149	7.24
MALS	142	11.01	72	14.08	86	12.97	207	8.67
UMALS	136	11.69	75	15.46	95	12.78	217	9.41
LMALS	141	12.35	63	17.82	74	15.42	194	9.64
LALS	184	29.06	40	12.79	89	32.45	173	44.93
AL2	141	8.78	85	15.26	134	17.70	116	7.97

The values of Cell Population Data show increased @LY Volume Mean and increased @LY Volume SD as compared with normal specimens.

NRBC



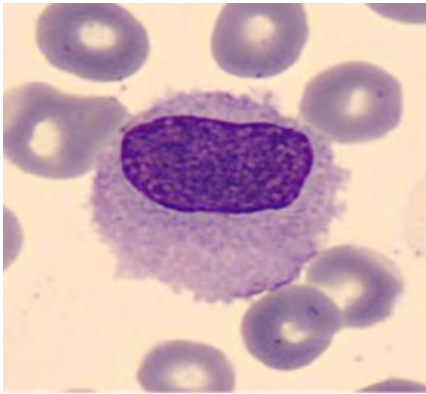
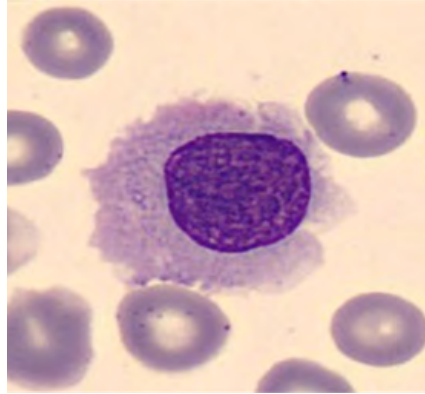
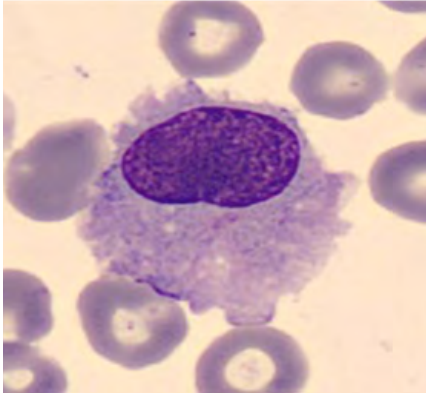
NRBC1 plot shows large lymphocyte population and some NRBC



For research use only. Not for use in diagnostic procedures.
@ - Research Use Only (RUO) parameters



BLOOD SMEAR



Manual Differential	
Neutrophils	37.5
Band Neutrophils	0
Lymphocytes	32
Monocytes	1.5
Eosinophils	2.5
Basophils	0.5
Metamyelocytes	0
Myelocytes	0
Promyelocytes	0
Immature Granulocytes	0
Atypical Lymphocytes	26
Blast	0
NRBC	0

Summary Results

- › Normal WBC count with slightly hypochromic normocytic anemia and thrombocytopenia
- › Lymphocytosis and monocytopenia; WBC histogram shows predominant LY population
- › 5PD1 plot (Scatter vs. Volume) and 5PD2 plot (Opacity vs. Volume) show abnormal lymphocyte population, lymphocyte macrocytosis, and anisocytosis
- › Abnormal lymphocytes with “hairy” cytoplasmic protrusions observed on the blood film

DIAGNOSIS: | HAIRY CELL LEUKEMIA



CASE 4 | ADULT T-CELL LEUKEMIA/LYMPHOMA

Disease Description

Adult T-cell leukemia/lymphoma (ATLL) is a rare but aggressive mature T-cell lymphoma caused by infection with the retrovirus human T-lymphotropic virus type 1 (HTLV-1).

ATLL is a disease of adults affecting individuals between 30-90 years with a male predominance (male:female ratio of 1.5:1).⁹

This disease is rare in the United States with an incidence of 0.05 per 100,000; however, in regions where the virus is endemic such as Japan, the Caribbean, and Central and South America, the incidence is as high as 27 per 100,000.¹⁰

The disease has a long latency period. Affected individuals acquire the virus many years before the development of lymphoma. The virus can be sexually transmitted or can be acquired through breast milk, transfusion of blood, and blood products.

Clinicopathologic Features⁴

ATLL can present clinically in one of several recognized variants—acute, lymphomatous, chronic, or smoldering. The acute variant is the most common, representing two-thirds of ATLL cases, followed by the lymphomatous form, representing approximately 20%.¹¹

While patients in both variants have similar clinical presentation including the development of skin lesions, generalized lymphadenopathy, hypercalcemia, and lytic lesions, the acute variant is characterized by leukocytosis due to leukemic presentation, which is not seen in the lymphomatous form.

In contrast to acute and lymphomatous forms, the chronic and smoldering variants lack leukocytosis and hypercalcemia. Skin lesions are present in both, while pulmonary lesions are especially seen in the smoldering form.

Lymphoma cells are numerous in the acute variant, whereas they are generally in low numbers in the chronic and smoldering forms. Typical lymphoma cells in circulation have irregular nuclei with ‘flower-like’ or ‘clover-shaped’ nuclear lobation.

ATLL in lymphnodes and skin or other organs has varied cytomorphologic features including diffuse infiltration by small, medium and large lymphoma cells, often admixed with anaplastic forms with pronounced nuclear irregularities and sometimes giant cells with cerebriform (markedly convoluted) nuclei.

Immunophenotype determined either by flow cytometry (in leukemic phase) and/or immunohistochemistry (particularly in lymph nodes, skin or other tissue forms) shows in the majority of cases, the lymphoma cells are CD4+, CD2+, CD3+, CD5+, T-cell receptor (TCR) αβ+, CD7-, and CD8- CD25 expression is characteristic.

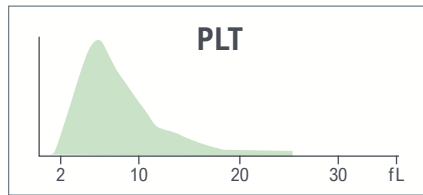
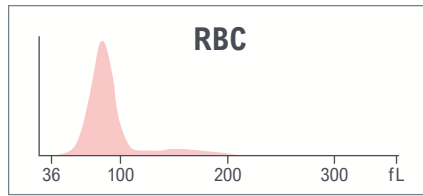
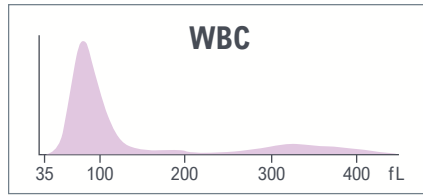
Confirmation of ATLL diagnosis is based on demonstration of positive HTLV-1 serology and clonal integration of HTLV-1 in tumor cell DNA using either Southern blot analysis or polymerase chain reaction (PCR).¹²



CBC parameters indicate leukocytosis and thrombocytosis with MPV at the low limit of reference ranges.

Yellow indicates an action limit is exceeded.

Test	Result	Flags
WBC	33.8	H
UWBC	33.8	H
RBC	4.57	
HGB	12.6	
HCT	39.1	
MCV	85.4	
MCH	27.5	
MCHC	32.2	L
RDW	13.9	
RDW-SD	40.7	
PLT	477	H
MPV	7.8	


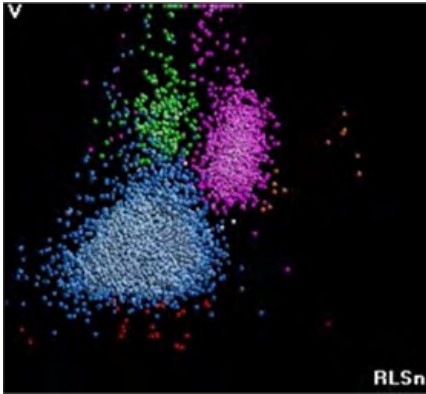


Test	Result	Flags
NE	19.6	L
LY	76.8	H
MO	3.0	L
EO	0.2	L
BA	0.4	
NE#	6.6	
LY#	26.0	aH
MO#	1.0	
EO#	0.1	
BA#	0.1	
NRBC	0.3	
NRBC#	0.10	H
MDW	26.36	

The results of the WBC automated differential show absolute lymphocytosis.

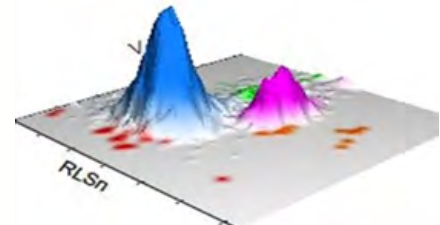


LEUKOCYTES



Suspect messages
• Variant LY

WBC Analysis 5PD1
3D Surface plot



5PD1 plot (Scatter vs. Volume) and 5PD2 plot (Opacity vs. Volume) show abnormal pattern for LY population as indicated by instrument messages.

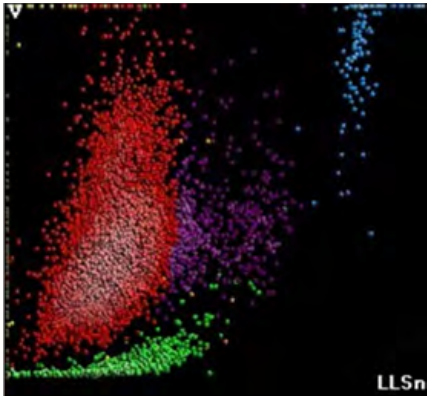
	NE		LY		MO		EO	
	Mean	SD	Mean	SD	Mean	SD	Mean	SD
V	162	24.04 ↑	94	20.13 ↑	186	23.61 ↑	147	19.62
C	142	4.36	116	7.95	122	6.90	147	4.97
MALS	139	11.43	84 ↑	18.25	94	11.10	184	22.72
UMALS	139	10.95	89	18.55	105	11.56	188	29.35
LMALS	133	13.79	73	22.88	80	15.57	175	17.78
LALS	177	30.85	44	15.67	75	27.82	201	24.76
AL2	146	12.55	79	13.78	130	15.19	128	17.95

The values of Cell Population Data show increased @NE Volume SD, increased @LY MALS Mean, increased @LY Volume SD, and increased @MO Volume SD as compared with normal specimen.

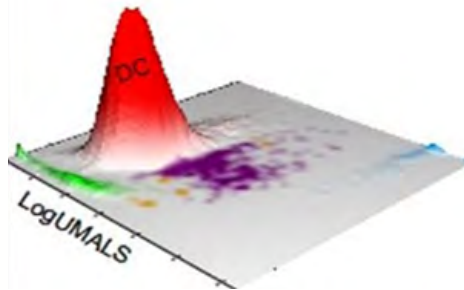
For research use only. Not for use in diagnostic procedures.
@ - Research Use Only (RUO) parameters



AUTOMATED RETICULOCYTE ANALYSIS




Abnormal distribution of the WBC population seen on RET1 showing the population of low-volume WBC

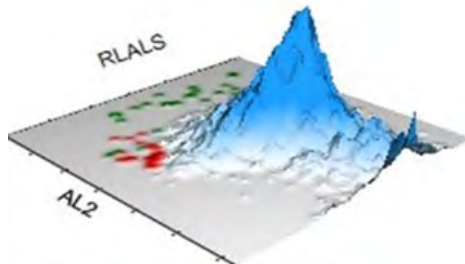


Test	Result	Flags
RET	1.50	
RET#	0.0687	
MRV	109.7	
IRF	0.43	

NRBC

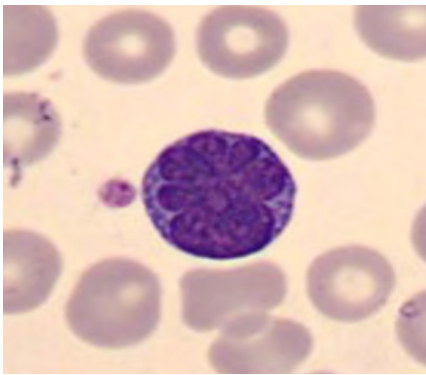
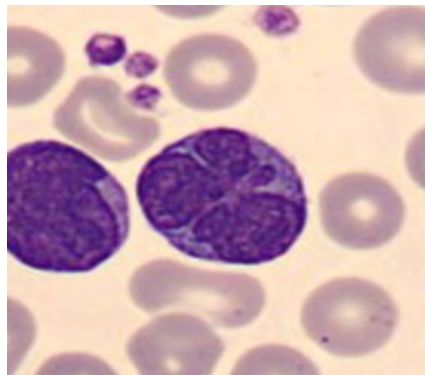
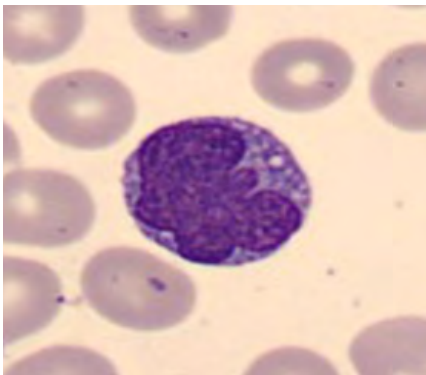
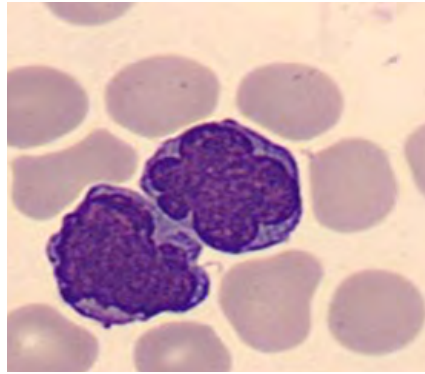
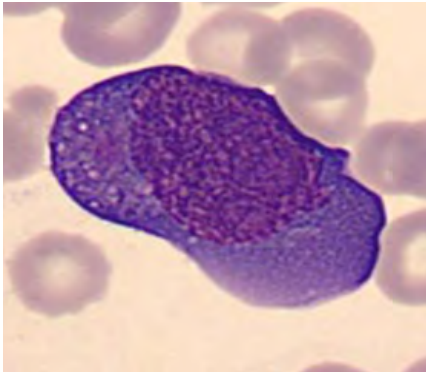


NRBC1 plot shows predominant LY population and few NRBC





BLOOD SMEAR



Manual Differential	
Neutrophils	19
Band Neutrophils	0
Lymphocytes	31
Monocytes	9.5
Eosinophils	0
Basophils	0.5
Metamyelocytes	
Myelocytes	
Promyelocytes	
Immature Granulocytes	0
Atypical Lymphocytes	40
Blast	0
NRBC	

Summary Results

- › Leukocytosis with absolute lymphocytosis
- › Slightly hypochromic RBC, normal RET, MRV, and IRF
- › Thrombocytosis and low MPV
- › 5PD1 plot (Scatter vs. Volume) and 5PD2 plot (Opacity vs. Volume) show lymphocyte anisocytosis and increased scatter of lymphocytes, anisocytosis of neutrophils and monocytes
- › Abnormal distribution of the WBC population seen on RET 1 showing the population of low-volume WBC
- › 40% of abnormal lymphocytes observed on the slide. A large proportion of abnormal lymphocytes with the typical convoluted “clover-leaf” nucleus

DIAGNOSIS: ADULT T-CELL LEUKEMIA/LYMPHOMA (ATLL)



CASE 5 | SÉZARY SYNDROME

Disease Description

Sézary syndrome (SS) is a rare but aggressive form of cutaneous T-cell lymphoma (CTCL) and accounts for less than 5% of all CTCLs.

It occurs in adults, characteristically presents over the age of 60 and has a male predominance.

The disease affects those of European ancestry more frequently than those of African ancestry.¹³⁻¹⁵

Overall prognosis is poor with a 5-year survival rate of 10-30%.

Diagnosis requires correlation of clinical, histologic, and molecular features as erythrodermic Mycosis Fungoides (MF) and SS show considerable overlap in presenting clinical features.

Even though SS and MF, especially erythrodermic type, share many similarities and are considered as a spectrum of cutaneous T-cell lymphoma, these are now believed to be distinct based on evidence that they originate from distinct memory T-cell subsets and show different clinical behaviors.^{16,17}

Clinicopathologic Features⁴

Clinically, patients with SS present with a triad of erythroderma, generalized lymphadenopathy, and the presence of clonal T-cells in peripheral blood.

Erythroderma is often exfoliative and pruritic. Lymph nodes are typically >1.5 cm in size. Other clinical manifestations of SS include alopecia and plantar and palmar hyperkeratosis.

Histopathologic features of skin lesions in SS may be indistinguishable from MF; however, they are more often non-specific and hence require clinical correlation in reaching the final diagnosis. Epidermotropism is reported to be less common in SS than in MF patients.

Peripheral blood involvement is the rule rather than the exception in SS. The circulating neoplastic lymphocytes, called Sézary cells, are large atypical lymphocytes with convoluted/cerebriform nuclei.

The International Society for Cutaneous Lymphomas (ISCL)/European Organization for Research and Treatment of Cancer (EORTC) guidelines for staging of SS require the presence of erythroderma, demonstration of clonal T-cells in peripheral blood, a total Sézary cell count of >1000/ μ L, a CD4:CD8 ratio of >10, and proliferation of CD4+ T-lymphocytes with abnormal immunophenotype (loss of CD7 or CD26 expression).¹⁸

Immunophenotyping either by immunohistochemistry (for skin lesions) and/or flow cytometry (particularly for peripheral blood) establishes the phenotype of the neoplastic cells. The neoplastic lymphocytes are typically CD3+, CD4+, and CD8- with frequent loss of CD5, CD7, and CD26.

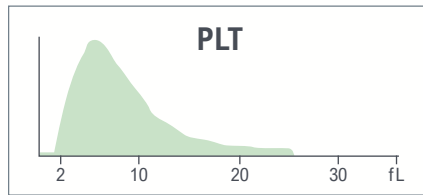
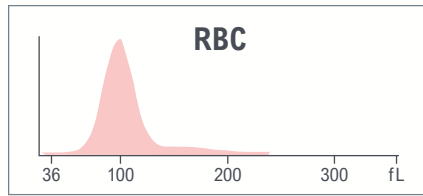
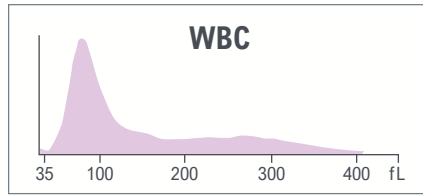
Per ISCL/EORTC guidelines, loss of CD7 in >40% and/or loss of CD26 in >30% of neoplastic lymphocytes is the recommended threshold for defining peripheral blood involvement in SS.



CBC parameters indicate leukocytosis, thrombocytopenia, and normocytic anemia with anisocytosis.

Yellow indicates an action limit is exceeded.

Test	Result	Flags
WBC	13.8	H
UWBC	13.8	H
RBC	3.80	L
HGB	12.0	L
HCT	36.8	
MCV	96.8	H
MCH	31.4	
MCHC	32.5	
RDW	15.5	
RDW-SD	52.9	H
PLT	135	L
MPV	8.4	





Test	Result	Flags
NE	24.4	L
LY	60.2	H
MO	7.6	
EO	5.7	
BA	2.1	H
NE#	3.4	
LY#	8.3	aH
MO#	1.0	
EO#	0.8	aH
BA#	0.3	H
NRBC	0.1	
NRBC#	0.02	

The results of the WBC automated differential show lymphocytosis, eosinophilia, and basophilia.



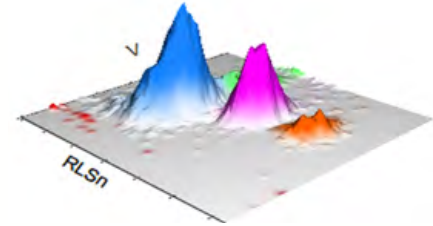
LEUKOCYTES



Suspect messages

- LY Blast
- Variant LY

WBC Analysis 5PD1
3D Surface plot

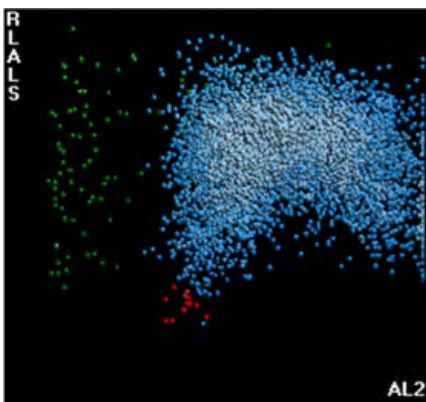


5PD1 plot (Scatter vs. Volume) and 5PD2 plot (Opacity vs. Volume) show abnormal patterns as indicated by the instrument messages.

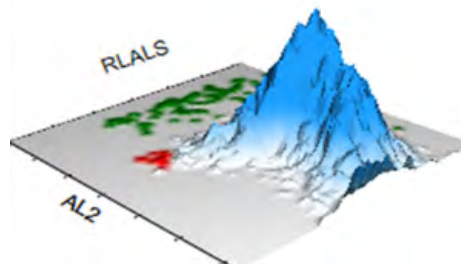
	NE		LY		MO		EO	
	Mean	SD	Mean	SD	Mean	SD	Mean	SD
V	153	20.92	114 ↑	25.12 ↑	189 ↑	24.84 ↑	158	17.46
C	155	5.37	127 ↑	7.71	134 ↑	7.84	159	5.82
MALS	140	11.44	77	16.44	89	12.64	196	9.54
UMALS	142	14.08	85	18.32	97	16.41	208	10.29
LMALS	135	12.28	66	19.17	77	16.04	181	11.51
LALS	159	28.48	46	16.26	80	29.46	149	37.95
AL2	148	12.39	104	17.65	164	15.14	131	10354

The values of Cell Population Data show increased @LY Volume Mean, increased @LY Volume SD, increased @Ly Conductivity Mean, increased @MO Volume Mean, increased @MO Volume SD, and increased @MO Conductivity Mean as compared with normal specimens.

NRBC



NRBC1 plot shows a large cluster of events corresponding to lymphocyte nuclei, some of which are large.

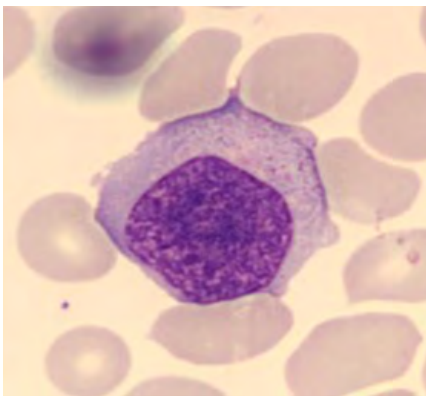
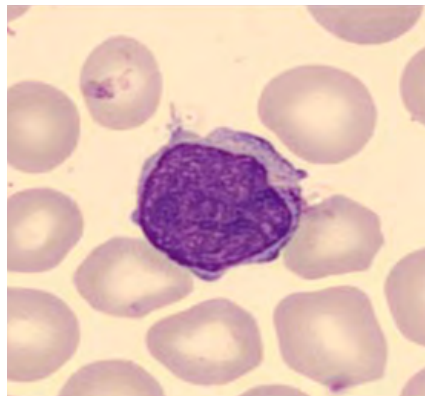
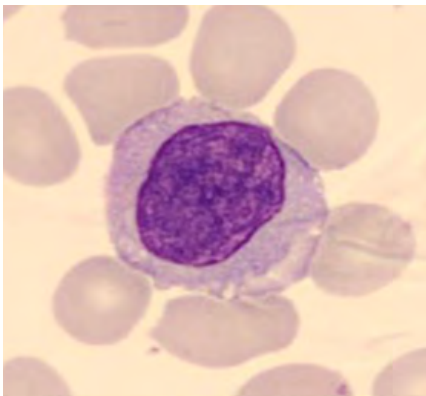
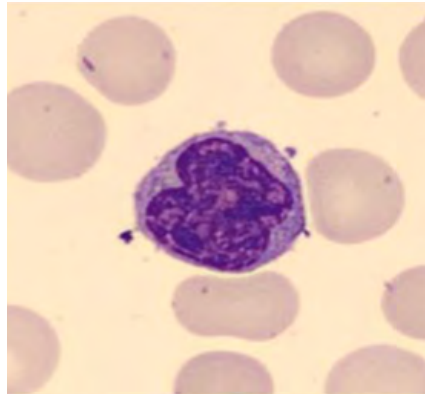
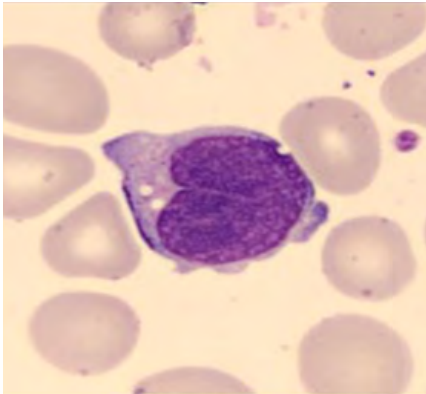


For research use only. Not for use in diagnostic procedures.

@ - Research Use Only (RUO) parameters



BLOOD SMEAR



Manual Differential	
Neutrophils	24
Band Neutrophils	0
Lymphocytes	61
Monocytes	7
Eosinophils	6
Basophils	2
Metamyelocytes	
Myelocytes	
Promyelocytes	
Immature Granulocytes	0
Atypical Lymphocytes	
Blast	
NRBC	

Summary Results

- › Normocytic anemia with anisocytosis; thrombocytopenia
- › Leukocytosis with lymphocytosis, eosinophilia, and basophilia
- › Abnormal patterns on 5PD1 and 5PD2 data plots with poor separation between LY and Mono
- › Blood film with several abnormal large lymphocytes with a large and cerebriform nucleus (Sézary cells)

DIAGNOSIS: SÉZARY SYNDROME



CASE 6 | T-CELL LYMPHOBLASTIC LEUKEMIA/LYMPHOMA

Disease Description

T-lymphoblastic leukemia (T-ALL) and T-lymphoblastic lymphoma (T-LBL) account for 15% of childhood and 25% of adult forms of acute lymphoblastic leukemia.

Childhood cases are more common in adolescent males, while adult disease is more common in patients beyond the adolescence age range.

T-ALL and T-LBL are the same diseases differing only in their mode of presentation. The term T-ALL is used when the disease presents primarily in blood or bone marrow, whereas the term T-LBL is used when the disease presents as a mediastinal or extranodal mass or with prominent lymphadenopathy without significant blood or bone marrow involvement.⁴

When a patient presents with a mass lesion as well as blood/bone marrow involvement, the distinction between leukemia and lymphoma is arbitrary, but in general, if there are >25% lymphoblasts in blood/bone marrow, the term T-ALL is used.

Compared to B-ALL, T-ALL more commonly presents with high-risk clinical features including older age, high WBC count, and frequent central nervous system involvement, and thus T-ALL is an aggressive disease.

Clinicopathologic Features⁴

Bone marrow failure is caused by the accumulation of malignant cells within marrow.

Organ infiltration can cause tender bones, lymphadenopathy, moderate splenomegaly, hepatomegaly, and meningeal syndrome.

Testicular swelling or signs of mediastinal compression are more common in T-ALL.

Infections are frequent, and anemia and thrombocytopenia are often profound.

Unlike acute myeloid leukemia where a blast threshold of >20% in blood or bone marrow is required to establish the diagnosis; no such threshold has been agreed upon for the diagnosis of B- or T-ALL.

The lineage of the blast cells is defined by microscopic examination (morphology), immunophenotypic (flow cytometry), and cytogenetic and molecular analysis. Cytomorphologically, blasts can have a heterogeneous appearances ranging from small to medium-sized with smudgy nuclear chromatin and inconspicuous nucleoli to larger blasts with finely dispersed chromatin and prominent nucleoli.

Immunophenotypically, T-lymphoblasts frequently express Terminal Deoxynucleotidyl Transferase (TdT). Variable expression of the T-cell antigens CD1a, CD2, CD3, CD4, CD5, CD7 and CD8 is observed. Four groups of T-ALLs are recognized based on antigen profiles: pro-T (CD7+), pre-T (CD2+ and/or CD5+ and/or CD8+), cortical T (CD1a+), and mature T (surface CD3+, CD1a-).¹⁹

Frequent structural genetic aberrations that define genetic subtypes of T-ALL involving transcription factor oncogenes such as basic helix-loop-helix genes, LIM-only domain (LMO) genes, homeobox (HOX) genes, and proto-oncogenes such as MYC and MYB are recognized.²⁰

Similarly, advances in molecular studies over the years have also identified recurrent molecular abnormalities in T-ALL involving the NOTCH pathway, cell cycle abnormalities, cell growth transcription factors, tumor suppressors, signal transduction, and chromatin remodeling.²⁰

Despite the genetic advances furthering our understanding of genetic basis and biology of T-ALL, the most recent WHO classification (WHO-HAEM5) deems the available literature evidence insufficient to propose genetic subtyping of T-ALL at this time.²¹

CBC parameters indicate leukocytosis and microcytosis without anemia.

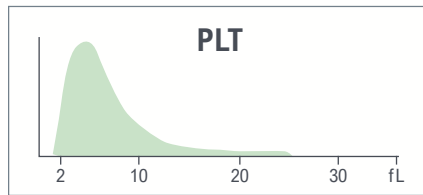
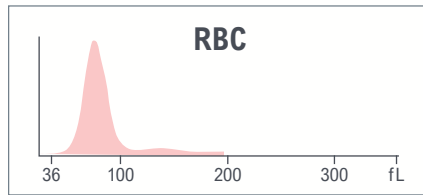
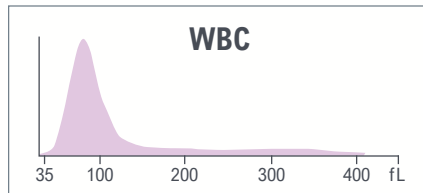
WBC histogram is abnormal and shows a single population.

Platelet count is in the normal range and MPV is low.

Red indicates a critical limit is exceeded.

Yellow indicates an action limit is exceeded.

Test	Result	Flags
WBC	47.5	H
UWBC	47.5	H
RBC	4.88	
HGB	12.6	
HCT	38.5	
MCV	78.9	
MCH	25.9	
MCHC	32.8	
RDW	14.2	
RDW-SD	38.1	
PLT	160	
MPV	7.0	L



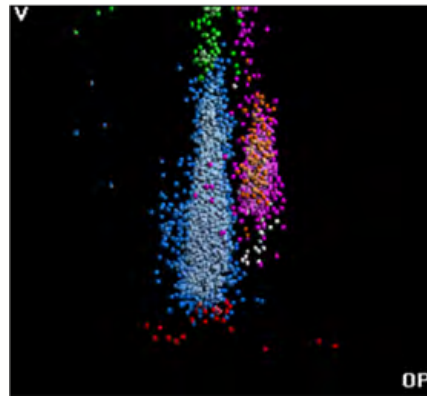
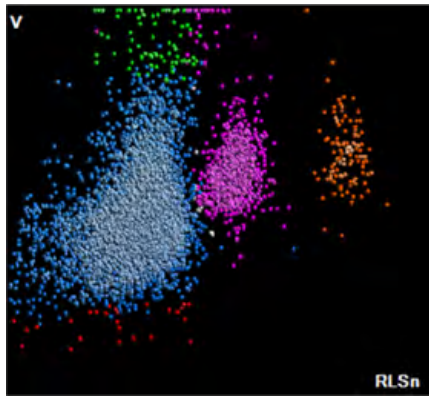
Test	Result	Flags
NE	10.6	L
LY	86.7	H
MO	0.9	L
EO	1.4	
BA	0.4	
NE#	5.0	
LY#	41.2	aH
MO#	0.4	
EO#	0.7	H
BA#	0.2	H
NRBC	1.3	aH
NRBC#	0.62	cH

The results of the WBC automated differential show lymphocytosis, eosinophilia, basophilia, and high NRBC.





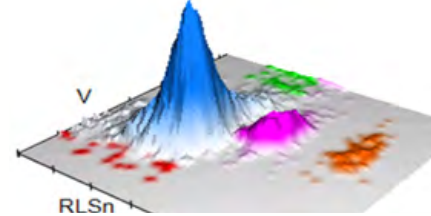
LEUKOCYTES



Suspect messages

- LY Blast
- Variant LY

WBC Analysis 5PD1
3D Surface plot

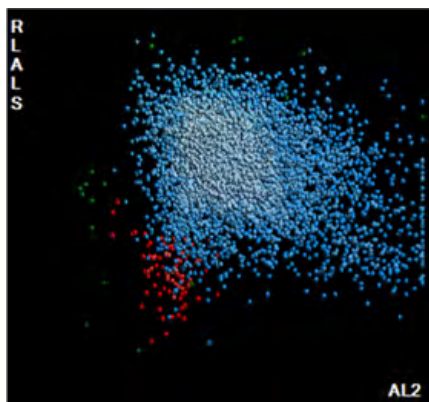


5PD1 plot (Scatter vs. Volume) and 5PD2 plot (Opacity vs. Volume) show abnormal patterns as indicated by instrument messages.

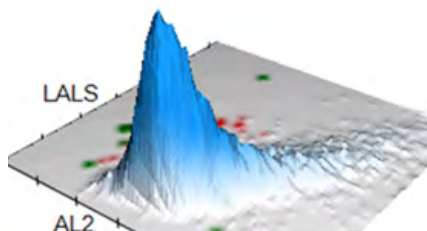
	NE		LY		MO		EO	
	Mean	SD	Mean	SD	Mean	SD	Mean	SD
V	152	26.36 ↑	115 ↑	25.87 ↑	235 ↑	15.41	159	21.96
C	150	5.72	120	5.71	119	16.01	150	4.58
MALS	138	10.52	78	18.61	88	17.11	207	8.35
UMALS	143	11.63	75	20.94	87	22.16	222	9.17
LMALS	129	13.21	75	21.66	85	16.10	188	11.32
LALS	190	34.94	56	25.78	100	40.03	197	48.09
AL2	137	13.79	80	16.25	113	31.29	116	10.37

The values of Cell Population Data show increased @LY Volume Mean, increased @LY Volume SD, increased @NE Volume SD, and increased @MO Volume Mean as compared with normal specimens.

NRBC



NRBC1 plot shows predominant population of lymphocytes and NRBC

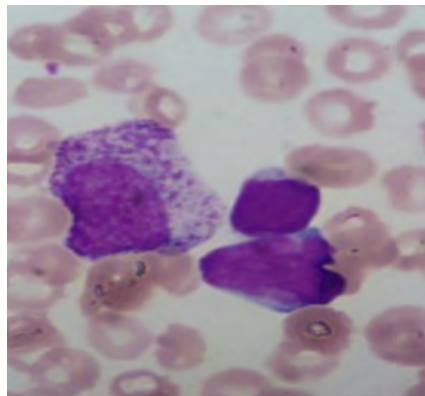
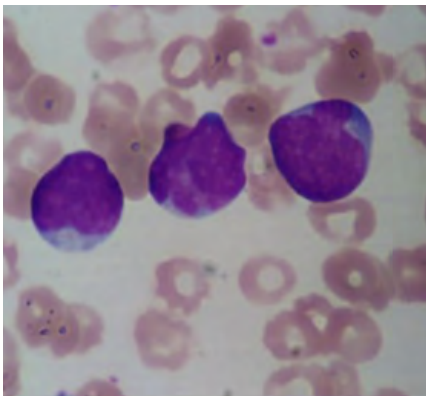
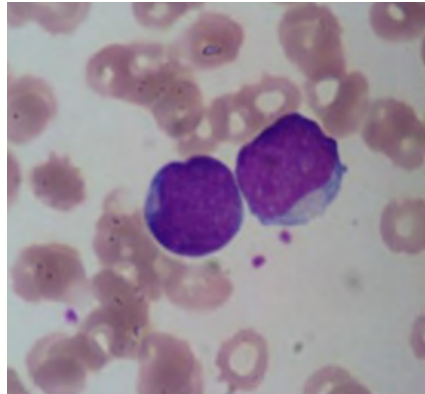
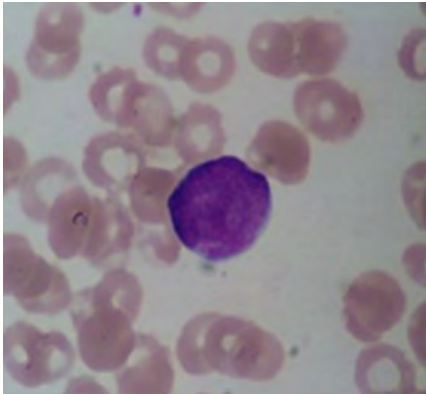


For research use only. Not for use in diagnostic procedures.

@ - Research Use Only (RUO) parameters



BLOOD SMEAR



Manual Differential	
Neutrophils	11
Band Neutrophils	
Lymphocytes	10
Monocytes	2
Eosinophils	2
Basophils	1
Metamyelocytes	
Myelocytes	
Promyelocytes	
Immature Granulocytes	0
Atypical Lymphocytes	
Blast	74
NRBC	1

Summary Results

- › Microcytosis without anemia, high NRBC
- › Normal PLT count with low MPV
- › Leukocytosis with eosinophilia, basophilia, and marked absolute lymphocytosis with variant lymph and LY Blast suspect messages on the analyzer
- › VCS analysis demonstrates an abnormal population of lymphocytes with macrocytosis and anisocytosis of lymphocytes, macrocytosis of monocytes, and anisocytosis of neutrophils as compared with normal specimens
- › Immature cells with large nuclei are observed on the blood film. Very abundant blast cells showing a high nucleus-cytoplasmic ratio and prominent nucleoli

DIAGNOSIS: T-CELL LYMPHOBLASTIC LEUKEMIA/LYMPHOMA



1. Hallek M, Cheson BD, Catovsky D, et al. iwCLL guidelines for diagnosis, indications for treatment, response assessment, and supportive management of CLL. *Blood*. 2018;131(25):2745-2760. doi:10.1182/blood-2017-09-806398
2. Binet JL, Auquier A, Dighiero G, et al. A new prognostic classification of chronic lymphocytic leukemia derived from a multivariate survival analysis. *Cancer*. 1981;48(1):198-206. doi:10.1002/1097-0142(19810701)48:1<198::aid-cnrcr2820480131>3.0.co;2-v
3. Robak E, Robak T. Skin lesions in chronic lymphocytic leukemia. *Leuk Lymphoma*. 2007;48(5):855-865. doi:10.1080/10428190601137336
4. WHO Classification of Tumours Editorial Board, Campo E, Harris NL, et al. *WHO Classification of Tumours of Haematopoietic and Lymphoid Tissues (Medicine)*. Revised. World Health Organization; 2017:585.
5. Bouroncle BA, Wiseman BK, Doan CA. Leukemic reticuloendotheliosis. *Blood*. 1958;13(7):609-630.
6. Andritsos LA, Grever MR. Historical overview of hairy cell leukemia. *Best Pract Res Clin Haematol*. 2015;28(4):166-174. doi:10.1016/j.beha.2015.10.018
7. Grever MR, Abdel-Wahab O, Andritsos LA, et al. Consensus guidelines for the diagnosis and management of patients with classic hairy cell leukemia. *Blood*. 2017;129(5):553-560. doi:10.1182/blood-2016-01-689422
8. Tiacci E, Park JH, De Carolis L, et al. Targeting Mutant BRAF in Relapsed or Refractory Hairy-Cell Leukemia. *N Engl J Med*. 2015;373(18):1733-1747. doi:10.1056/NEJMoa1506583
9. Yamaguchi K. Human T-lymphotropic virus type I in Japan. *Lancet*. 1994;343(8891):213-216. doi:10.1016/s0140-6736(94)90994-6
10. Mirabello L, Troisi RJ, Savage SA. International osteosarcoma incidence patterns in children and adolescents, middle ages and elderly persons. *Int J Cancer*. 2009;125(1):229-234. doi:10.1002/ijc.24320
11. Mehta-Shah N, Ratner L, Horwitz SM. Adult T-Cell Leukemia/Lymphoma. *J Oncol Pract*. 2017;13(8):487-492. doi:10.1200/JOP.2017.021907
12. Tsukasaki K, Tsushima H, Yamamura M, et al. Integration patterns of HTLV-I provirus in relation to the clinical course of ATL: frequent clonal change at crisis from indolent disease. *Blood*. 1997;89(3):948-956. doi:10.1182/blood.V89.3.948
13. Criscione VD, Weinstock MA. Incidence of cutaneous T-cell lymphoma in the United States, 1973-2002. *Arch Dermatol*. 2007;143(7):854-859. doi:10.1001/archderm.143.7.854
14. Bradford PT, Devesa SS, Anderson WF, Toro JR. Cutaneous lymphoma incidence patterns in the United States: a population-based study of 3884 cases. *Blood*. 2009;113(21):5064-5073. doi:10.1182/blood-2008-10-184168
15. Kubica AW, Davis MDP, Weaver AL, Killian JM, Pittelkow MR. Sézary syndrome: a study of 176 patients at Mayo Clinic. *J Am Acad Dermatol*. 2012;67(6):1189-1199. doi:10.1016/j.jaad.2012.04.043
16. Martinez XU, Di Raimondo C, Abdulla FR, Zain J, Rosen ST, Querfeld C. Leukaemic variants of cutaneous T-cell lymphoma: Erythrodermic mycosis fungoides and Sézary syndrome. *Best Pract Res Clin Haematol*. 2019;32(3):239-252. doi:10.1016/j.beha.2019.06.004
17. Spicknall KE. Sézary syndrome-clinical and histopathologic features, differential diagnosis, and treatment. *Semin Cutan Med Surg*. 2018;37(1):18-23. doi:10.12788/j.sder.2018.005
18. Olsen E, Vonderheid E, Pimpinelli N, et al. Revisions to the staging and classification of mycosis fungoides and Sézary syndrome: a proposal of the International Society for Cutaneous Lymphomas (ISCL) and the cutaneous lymphoma task force of the European Organization of Research and Treatment of Cancer (EORTC). *Blood*. 2007;110(6):1713-1722. doi:10.1182/blood-2007-03-055749
19. Bene MC, Castoldi G, Knapp W, et al. Proposals for the immunological classification of acute leukemias. European Group for the Immunological Characterization of Leukemias (EGIL). *Leukemia*. 1995;9(10):1783-1786.
20. Van Vlierberghe P, Ferrando A. The molecular basis of T cell acute lymphoblastic leukemia. *J Clin Invest*. 2012;122(10):3398-3406. doi:10.1172/JCI61269
21. Alaggio R, Amador C, Anagnostopoulos I, et al. The 5th edition of the World Health Organization Classification of Haematolymphoid Tumours: Lymphoid Neoplasms. *Leukemia*. 2022;36(7):1720-1748. doi:10.1038/s41375-022-01620-2



Myeloid Neoplasms

Acute and Chronic

CASE 1	Chronic Myeloid Leukemia
CASE 2	Myelodysplastic Syndrome
CASE 3	Acute Myeloid Leukemia
CASE 4	Acute Panmyelosis with Myelofibrosis
CASE 5	Acute Monocytic Leukemia
CASE 6	Acute Myeloid Leukemia-M2 at Relapse
CASE 7	Acute Myeloid Leukemia at Diagnosis



CASE 1 | CHRONIC MYELOID LEUKEMIA

Disease Description

Chronic myeloid leukemia (CML) is a chronic myeloproliferative neoplasm occurring at an annual rate of 1-2 cases per 100,000 population. Approximately 15% of newly diagnosed adult leukemia cases are CML.

CML is a disorder of the hematopoietic stem cells and is characterized by a balanced genetic translocation, t(9;22)(q34;q11.2) whereby the Abelson murine leukemia (ABL1) gene on chromosome 9 fuses with the breakpoint cluster region (BCR) gene on chromosome 22, leading to the formation of the Philadelphia (Ph) chromosome. The resulting *BCR-ABL1* fusion oncogene gives rise to the fusion oncoprotein BCR-ABL1.

Clinicopathologic Features^{1,2}

CML is asymptomatic in approximately half of patients and is diagnosed on a routinely performed complete blood count. WBC count is usually $>50 \times 10^9/L$.

Patients with symptoms may show symptoms related to anemia including fatigue and malaise. They may have weight loss or night sweats. Splenomegaly (enlarged spleen) is a common finding in CML patients. Patients with thrombocytopenia may show hemorrhagic diathesis because of abnormal platelet function.

Sometimes, CML may have an atypical presentation in the form of thrombocytosis, which can result in thrombotic episodes or priapism.

Patients with advanced stages of CML may experience fever, bone pain, joint pain, bleeding, infections, and lymphadenopathy.

PERIPHERAL BLOOD FINDINGS

Leukocytosis due to granulocytic proliferation with a predominance of myelocytes and mature neutrophils is characteristic in the most common form of presentation, which is the chronic phase. There is basophilia and/or eosinophilia. Blasts are not significantly increased, and no dysplasia is seen. Red blood cells are normocytic normochromic. Platelet count is most frequently increased.

BONE MARROW FINDINGS

In a typical chronic phase CML, the core biopsy is hypercellular for age with predominantly marked granulocytic proliferation with complete maturation and decreased erythropoiesis. Megakaryocytes are also increased, and they are characteristically small and with hypolobated nuclei (commonly referred to as 'dwarf' megakaryocytes).

Aspirates show a predominance of granulocytic lineage cells at all stages of maturation but with a predominance of myelocytes and mature neutrophils. In addition, basophils and sometimes eosinophils are increased. Characteristically, aspirates also show the presence of pseudo-Gaucher cells.

Disease progression typically occurs progressively in stages from the indolent chronic phase to the accelerated phase to the blast phase.

Diagnosis of CML rests on the detection of Ph chromosome or *BCR-ABL1* by fluorescent in situ hybridization (FISH) and/or reverse transcriptase-polymerase chain reaction (rtPCR).



CBC parameters indicate leukocytosis, thrombocytosis, and microcytic hypochromic anemia with anisocytosis.

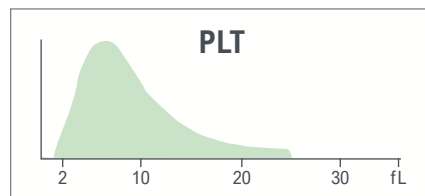
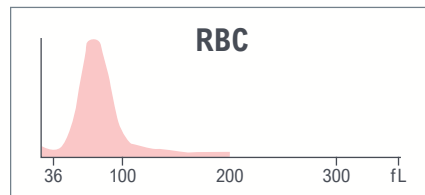
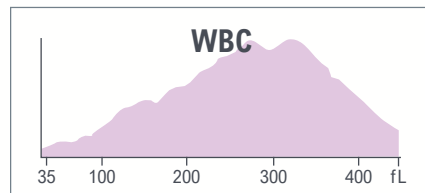
A slight rise on the left of the RBC histogram and the right of the PLT histogram might indicate red cell fragments, although the patterns are not abnormal enough to trigger the RBC Frag/Microcytes Suspect message.

WBC histogram shows a single population with an extension on the right side.

Red indicates a critical limit is exceeded.

Yellow indicates an action limit is exceeded.



Test	Result	Flags
WBC	135.8	cH
UWBC	135.8	cH
RBC	4.32	
HGB	10.1	L
HCT	32.7	L
MCV	75.6	
MCH	23.3	L
MCHC	30.8	aL
RDW	19.4	aH
RDW-SD	51.2	H
PLT	1002	cH
MPV	8.8	



Test	Result	Flags
NE	82.0	H
LY	3.2	L
MO	6.8	
EO	2.5	
BA	5.5	aH
NE#	111.5	cH
LY#	4.3	H
MO#	9.2	aH
EO#	3.4	aH
BA#	7.4	aH
NRBC	0.2	
NRBC#	0.23	cH
MDW	97.70	

The results of the WBC automated differential show neutrophilia, lymphocytosis, monocytosis, eosinophilia, basophilia, and high NRBC.

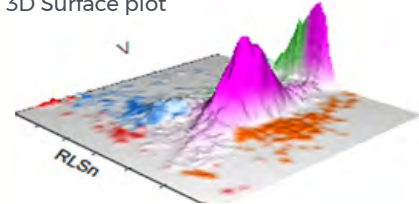
LEUKOCYTES



Suspect messages

- Left Shift
- Imm Grans
- Ne Blasts

WBC Analysis 5PD1
3D Surface plot



5PD1 plot (Scatter vs. Volume) and 5PD2 plot (Opacity vs. Volume) show abnormal patterns as indicated by the instrument messages.

	NE		LY		MO		EO	
	Mean	SD	Mean	SD	Mean	SD	Mean	SD
V	161	42.71 ↑	106 ↑	51.27 ↑	224 ↑	39.47 ↑	150	38.44
C	133 ↓	8.25	110	21.84	118	18.03	141	7.78
MALS	139	14.95	73	28.17	98	15.46	193	14.23
UMALS	148	19.33	80	28.75	107	17.64	208	15.10
LMALS	126	15.58	61	28.93	87	17.53	174	16.20
LALS	148	34.33	55	46.16	107	41.98	153	41.27
AL2	146	25.84	71	15.90	154	42.83	144	24.73

The values of Cell Population Data show increased @NE Volume SD, increased @LY Volume Mean, increased @LY Volume SD, increased @MO Volume Mean, increased @MO Volume SD, and decreased NE Conductivity Mean as compared with normal specimen.

For research use only. Not for use in diagnostic procedures.
 @ - Research Use Only (RUO) parameters



Benign Categories

Lymphoid Neoplasms

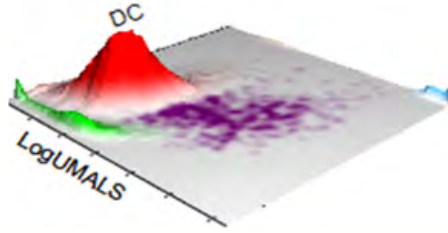

Myeloid Neoplasms/
Myelodysplastic Syndromes

Red Blood Cell Disorders





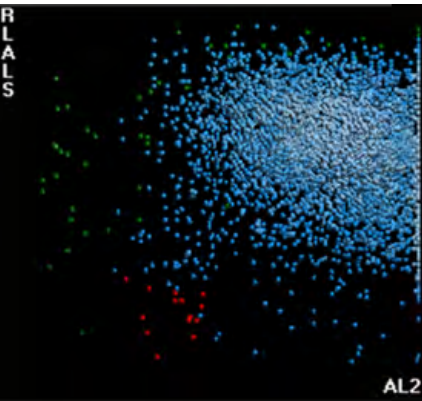
AUTOMATED RETICULOCYTE ANALYSIS



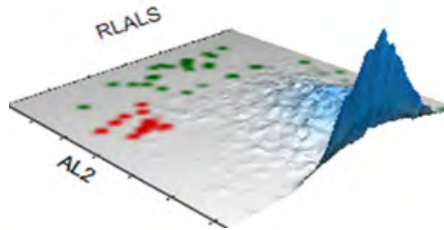
Test	Result	Flags
RET	2.33	H
RET#	0.1007	
MRV	108.4	
IRF	0.63	H

High Retics and high IRF

NRBC

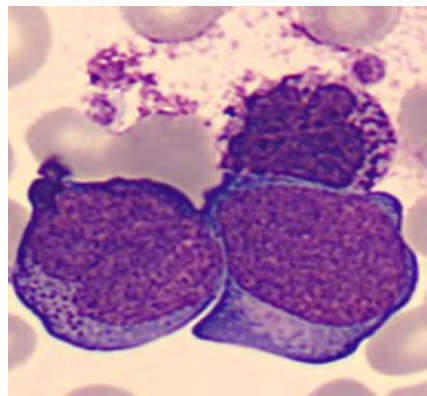
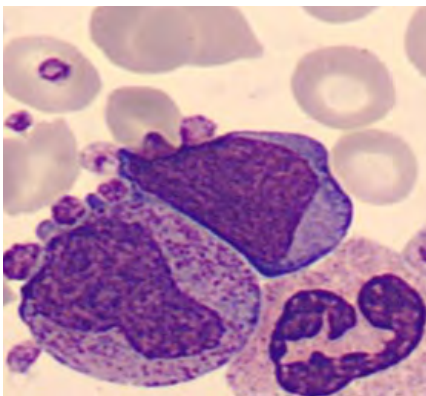
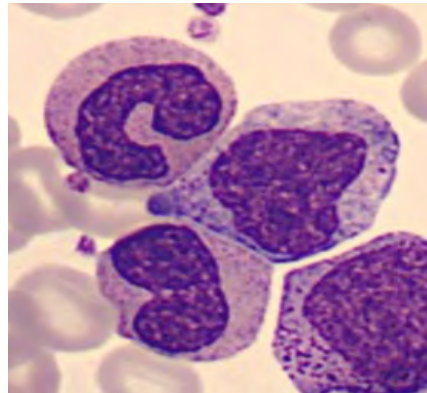
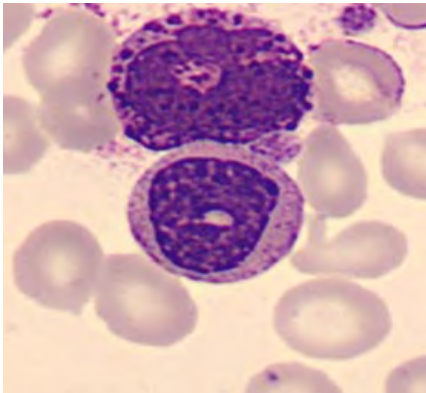
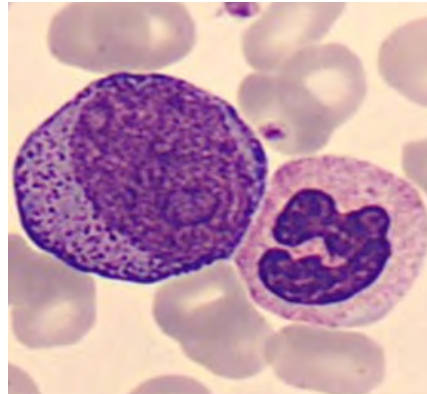
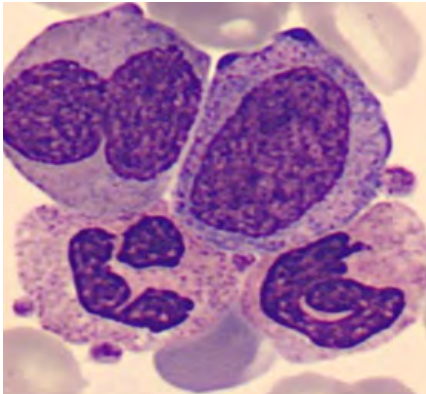


NRBC1 plot shows uniform population, which represents neutrophils and some NRBC.





BLOOD SMEAR



Manual Differential	
Neutrophils	59
Band Neutrophils	12
Lymphocytes	3.5
Monocytes	4
Eosinophils	1
Basophils	5.5
Metamyelocytes	
Myelocytes	
Promyelocytes	
Immature Granulocytes	15
Atypical Lymphocytes	
Blast	
NRBC	

Comments:

Microcytic hypochromic anemia may be related to an underlying iron deficiency or hemoglobinopathy and has no contribution to the diagnosis of chronic myeloid leukemia. Serum iron and ferritin levels as well as hemoglobin electrophoresis may help determine the etiology for microcytic hypochromic anemia in this case.

Summary Results

- › Microcytic hypochromic anemia with anisocytosis, high NRBC
- › High Retics and IRF
- › Thrombocytosis with normal MPV
- › Leukocytosis with neutrophilia, lymphocytosis, monocytosis, eosinophilia, and basophilia
- › The 5PD1 and 5PD2 data plots show abnormal patterns
- › Immature granulocytes and bands are observed on the blood film

DIAGNOSIS: CHRONIC MYELOID LEUKEMIA (CML)



CASE 2 | MYELOYDYSPLASTIC SYNDROME

Disease Description

The term myelodysplastic syndrome (MDS) refers to a disease spectrum caused by a clonal defect at the stem cell level that leads to ineffective hematopoiesis or bone marrow failure manifesting as one or more cytopenias, dysplastic cytomorphology in one or more of the hematopoietic lineages, chromosomal and copy-number alterations, and somatic mutations in driver and non-driver genes.

MDS is usually a disease of older individual (60 years above) and occurs more frequently in males than in females.

Overall, patients with MDS have an increased risk of transformation to acute myelogenous leukemia (AML).

Old age; prior exposure to chemotherapy or radiation; exposure to environmental and occupational carcinogens such as benzene, chemical fertilizers, nitro-organic explosives and diesel; and some inherited genetic syndromes such as Fanconi anemia, Shwachman-Diamond syndrome, familial platelet disorder, and severe congenital neutropenia are some of the known risk factors for development of MDS.

In the latest (2022) WHO classification of hematologic neoplasia, MDS has been renamed myelodysplastic neoplasm to emphasize the neoplastic nature of this disease.

Clinicopathologic Features^{1,2}

MDS is suspected when a patient develops one or more cytopenias that are persistent or progressive and without evidence of any reactive etiologies that can be attributed to the low counts.

The recommended thresholds to define cytopenias established in the original International Prognostic Scoring System (IPSS) have been slightly modified in the 5th edition of the World Health Organization Classification of Tumours of Haematolymphoid and Lymphoid Tissues.¹ They include Hb <13 g/dL in males and <12 g/dL in females for anemia, absolute neutrophil count <1.8 ×10⁹/L for leukopenia, and platelets <150 ×10⁹/L for thrombocytopenia.

Anemia manifests in the form of pallor, lethargy, and dyspnea. Patients with neutropenia are prone to recurrent infections, while thrombocytopenia leads to easy bruising or bleeding.

LABORATORY FINDINGS

Peripheral blood:

Pancytopenia is a frequent finding. RBCs are usually macrocytic but occasionally hypochromic. The reticulocyte count is low. Granulocytes are often reduced in number and frequently show hypogranulation. The pseudo-Pelger-Huët abnormality (i.e., single or bilobed nucleus of neutrophils) is often present. The platelets are usually decreased in number.

Bone Marrow:

The WHO recommends evaluation of bone marrow biopsy, as well as bone marrow aspirates. The presence of morphologic dysplasia with the recommended threshold for dysplasia is set at 10% for all lineages.



Clinicopathologic Features^{1,2}

Dysplastic features in erythroid lineage cells can include nuclear irregularities such as nuclear budding, internuclear bridging, karyorrhexis, and multinucleation. Erythroid precursors are frequently megaloblastic in size.

Dysgranulopoiesis manifests in the form of abnormal nuclear segmentation which can be hypersegmentation or hyposegmentation (pseudo-Pelger-Huët anomaly), cytoplasmic hypogranulation, and Chédiak-Higashi granules.

Dysplastic features in megakaryocytes manifest as micromegakaryocytes, small megakaryocytes with hypo/monolobated nuclei, or megakaryocytes with separated nuclear lobes.

Aspirates are also evaluated for an increased percentage of blast cells, a critical parameter for the classification of MDS. Blast percentages in the 5th WHO classification divide MDS into MDS with low blasts (<5% Bone Marrow and <2% Peripheral Blood) and MDS with increased blasts 1 and 2 (MDS-IB1 5-9% Bone Marrow or 2-4% Peripheral Blood; MDS-IB2 10-19% Bone Marrow or 5-19% Peripheral Blood).

The bone marrow core biopsy is typically hypercellular for age. In approximately 10% of cases, the marrow can be hypocellular. In the latter situation, the 5th edition of the WHO classification recognizes hypoplastic MDS as a distinct MDS type in which hypocellularity is defined by $\leq 25\%$ bone marrow cellularity, age-adjusted. Another 10-15% of MDS cases can exhibit significant (grade 2 or 3) myelofibrosis.

IMMUNOPHENOTYPIC ANALYSIS IN MDS

Immunohistochemical stains and special stains can be useful in certain cases. A panel of markers commonly used includes CD34, CD117, one megakaryocyte marker (CD61 or CD42b), and one erythroid marker (glycophorin-A or -C). Special stains, Reticulin and Masson Trichrome, are used to assess the degree of myelofibrosis in cases where fibrosis is evident.

CD34 is useful in highlighting abnormal clusters of CD34+ blasts in suspected MDS cases. CD117 is used as a surrogate marker in cases when blasts are CD34-. Since CD117 can also be expressed in erythroid progenitors, Glycophorin A/C can aid in the distinction of blasts from erythroid progenitors. Megakaryocytic lineage markers CD61 or CD42b are useful in identifying atypical cytologic features (dwarf forms including micromegakaryocytes) and abnormal distribution.

Multiparameter flow cytometry (FCM) is an important complementary tool that can aid in the diagnosis of MDS but in and of itself is insufficient in establishing a primary diagnosis of MDS. FCM can have utility in enumerating blast percentages; detecting aberrant immunophenotypes on the blasts; and detecting aberrant maturation profiles on maturing granulocytic, erythroid, and monocytic lineage cells.



Clinicopathologic Features^{1,2}

GENETIC AND MOLECULAR ANALYSIS IN MDS

Cytogenetic analysis (fluorescence in situ hybridization and conventional karyotyping) not only plays a pivotal role by establishing clonality in the diagnosis of MDS but also aids in correlation with specific morphologic and clinical characteristics, disease prognostication, and risk-stratification.

The commonly occurring genetic abnormalities (Y-, del 5q, del 20q, del 12p, del 7q, +8, +19, i17q, inv3) were categorized into 5 prognostic subgroups by The Comprehensive Cytogenetic Scoring System (CCSS) for MDS patients. The cytogenetic subgroups of CCSS are incorporated into the revised International Prognostic Scoring System (IPSS-R) score for MDS.^{3,4}

The discovery of >40 recurrently mutated genes associated with MDS has led to increased use of Next-generation sequencing (NGS) assays to detect MDS-associated gene mutations as many of these gene mutations have significant predictive and prognostic value in MDS. A detailed description of the mutations is beyond the scope of this text.

The impact of genetic and mutational abnormalities on MDS diagnosis has prompted the 5th edition of WHO classification to regroup myelodysplastic neoplasms into those having defining genetic abnormalities and those that are morphologically defined. The group of MDS with defining genetic abnormalities includes MDS with low blasts and isolated 5q deletion (MDS-5q), MDS with low blasts and SF3B1 mutation (MDS-SF3B1), and MDS with biallelic TP53 inactivation (MDS-biTP53).



CBC parameters indicate normocytic normochromic anemia and thrombocytopenia.

Abnormal WBC histogram shows interference at 35 fL and large peak between 100 fL and 300 fL.

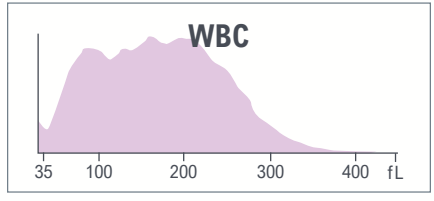
Abnormal PLT histogram with interference in the left side (debris) and extension beyond 25 fL may indicate presence of PLT Clumps/Giant Platelets.

PLT-related results are flagged for review.

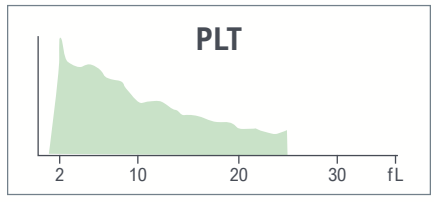
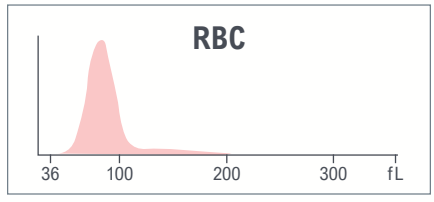
Red indicates a critical limit is exceeded.

Yellow indicates an action limit is exceeded.

Test	Result	Flags
WBC	8.5	
UWBC	8.5	
RBC	2.75	L
HGB	8.3	aL
HCT	24.3	L
MCV	88.3	
MCH	30.2	
MCHC	34.2	
RDW	15.1	
RDW-SD	44.6	
PLT	24	RcL
MPV	10.8	R



System message
• PLT Inter: Debris

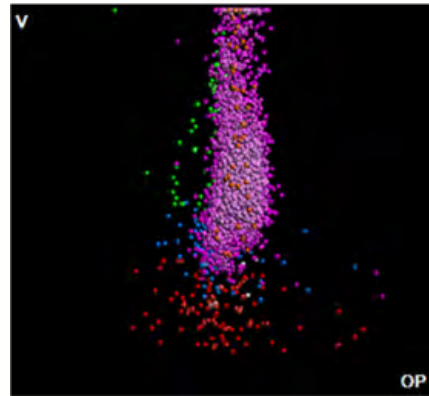



Test	Result	Flags
NE	93.3	H
LY	2.0	L
MO	3.8	L
EO	0.8	
BA	0.1	L
NE#	7.9	H
LY#	0.2	L
MO#	0.3	
EO#	0.1	
BA#	0.0	
NRBC	0.1	
NRBC#	0.01	

The results of the WBC automated differential show neutrophilia and lymphopenia.



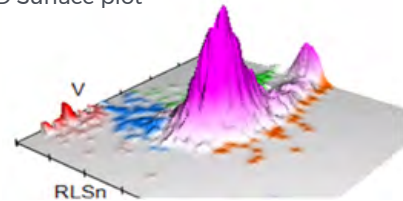
LEUKOCYTES



Suspect messages

- Imm Gran
- Left Shift
- NE Blast

WBC Analysis 5PD1
3D Surface plot




5PD1 plot (Scatter vs. Volume) and 5PD2 plot (Opacity vs. Volume) show abnormal patterns, indicated by multiple instrument messages, with single predominant population neutrophils.

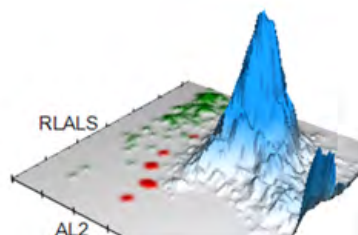
	NE		LY		MO		EO	
	Mean	SD	Mean	SD	Mean	SD	Mean	SD
V	147	34.77 ▲	94	14.47	187	27.33	178	52.63
C	139 ▼	8.67	124	17.08	126	9.87	137	5.11
MALS	109 ▼	14.91	53	21.97	78	15.90	153	11.75
UMALS	112	19.22	57	28.27	88	17.95	160	14.87
LMALS	103	15.53	43	22.40	64	17.74	142	11.13
LALS	125	45.63	36	20.54	72	34.00	112	35.99
AL2	140	24.21	80	16.29	140	22.15	164	33.60

The values of Cell Population Data show increased @NE Volume SD, decreased @NE MALS Mean, and decreased @NE Conductivity Mean as compared with normal specimen.

NRBC



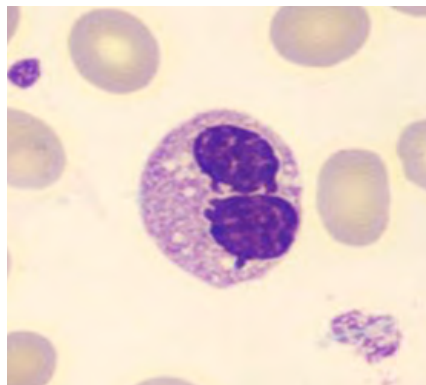
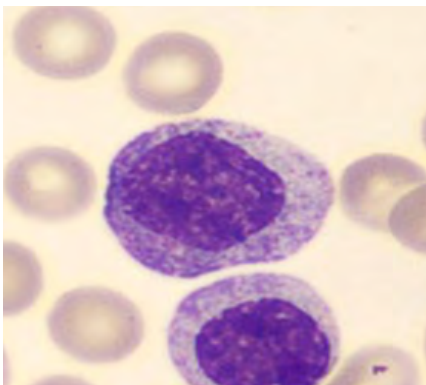
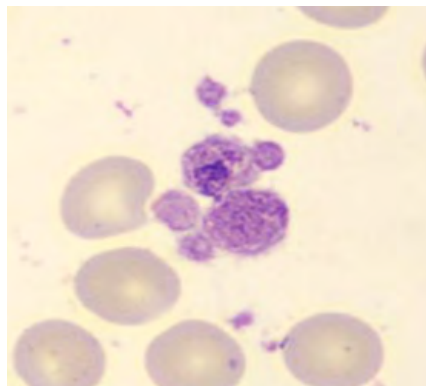
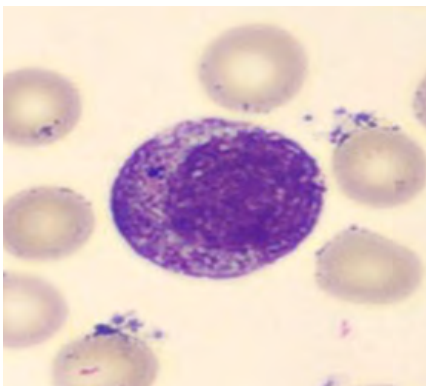
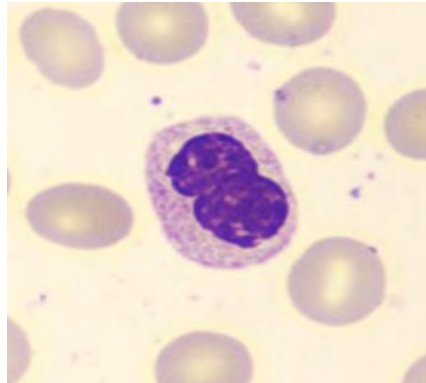
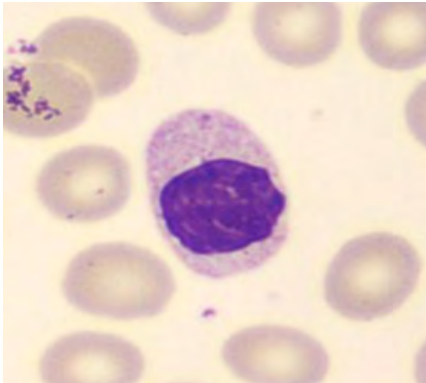
NRBC1 plot shows green population that may indicate presence of some large platelets, but it is not big enough to trigger suspect message Giant Platelets.



For research use only. Not for use in diagnostic procedures.
@ - Research Use Only (RUO) parameters



BLOOD SMEAR



Manual Differential	
Neutrophils	55
Band Neutrophils	
Lymphocytes	5
Monocytes	5
Eosinophils	2
Basophils	0
Metamyelocytes	
Myelocytes	
Promyelocytes	
Immature Granulocytes	30
Atypical Lymphocytes	
Blast	3
NRBC	

Comments:

Few large platelets

While the peripheral blood features suggest the diagnosis of MDS, the final diagnosis of MDS requires the incorporation of data from bone marrow examination as well as cytogenetics. Please refer to the text on general description of MDS for more details.

Neutrophilia observed in this case is not a feature in typical MDS cases. Other causes (reactive) must be investigated to attribute the neutrophilia.

Summary Results

- › Normocytic anemia
- › Thrombocytopenia, with few large platelets are observed on the blood film
- › Normal WBC count with neutrophilia and lymphopenia
- › VCS analysis demonstrates anisocytosis of neutrophils, low scatter, and low conductivity for neutrophils
- › Hypogranulated neutrophils and 30% immature granulocytes are seen on the blood film
- › Several dysplastic neutrophils observed on the blood smear characterized by hypogranularity, nucleus hyposegmentation, or round nuclei

DIAGNOSIS: MYELOYDYSPLASTIC SYNDROME



CASE 3 | ACUTE MYELOID LEUKEMIA

Disease Description

Acute myeloid leukemia (AML) is a malignancy of hematopoietic stem cell precursors arising in the bone marrow and causing bone marrow failure. The disease is associated with qualitative and quantitative abnormalities of hematopoietic cells in peripheral blood and bone marrow.

While AML accounts for only 1.2% of all newly diagnosed cancer cases in the United States per year, it accounts for 15–20% and 35% of leukemias in children and adults, respectively.⁵

A hallmark of the disease is simultaneous proliferation and apoptosis of hematopoietic cells leading to cellular proliferation in the marrow but with peripheral pancytopenia. The impaired hematopoiesis leads to dysfunctional neutrophils, monocytes, and platelets.

The diagnosis is established by the presence of 20% or more myeloid blasts in peripheral blood or bone marrow aspirates but in the context of certain recurrent genetic abnormalities e.g., t [t(8;21), inv(16), or t(15;17)], the blast count is irrelevant, and the latter cases are diagnosed regardless of the percentage of blasts in the blood or bone marrow.⁶

Clinicopathologic Features

While some patients will be diagnosed on routine blood work, most patients present with a myriad of signs and symptoms secondary to ineffective erythropoiesis or bone marrow failure. Patients commonly present with recurrent infections, anemia, bruising, bleeding from gums or other mucosal sites, and disseminated intravascular coagulation.

Severe anemia can manifest in the form of easy fatigability, shortness of breath, and generalized weakness. Organ infiltration by leukemic cells is common and can manifest in the form of hepatosplenomegaly, skin rashes, and rarely lymphadenopathy.

LABORATORY FINDINGS

Pancytopenia is a common feature. Peripheral blood may show features of disseminated intravascular coagulation, which includes the presence of schistocytes and polychromasia. Blasts are often present and can vary from occasional to greater than 20%. In cases where the blasts are $\geq 20\%$, diagnosis of acute myeloid leukemia can be made using peripheral blood.

Maturing myeloid cells such as granulocytes often display dysplastic features including pseudo-Pelger-Huët anomaly, hypogranular cytoplasm, or abnormal inclusions. Platelets can show giant and hypogranular forms.

NOTE: The final categorization of acute myeloid leukemia rests upon ancillary studies to evaluate for recurring cytogenetic abnormalities or certain mutations. Morphologically defined categorization is done only after the exclusion of genetically defined acute myeloid leukemias.



CBC parameters indicate normocytic normochromic anemia and critical thrombocytopenia.

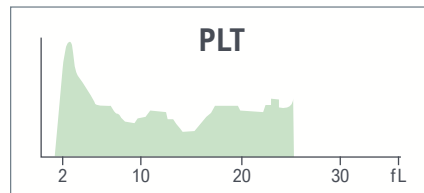
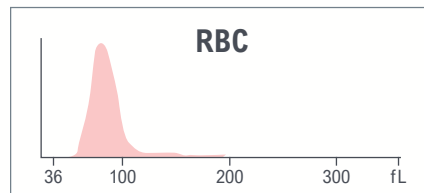
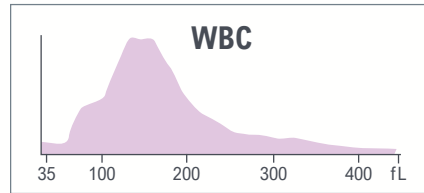
WBC histogram shows a predominant subpopulation of cells.

An abnormal **PLT histogram** is seen, but the platelet count is reported without any flag for review.

Red indicates a critical limit is exceeded.

Yellow indicates an action limit is exceeded.

Test	Result	Flags
WBC	8.3	
UWBC	8.3	
RBC	2.80	L
HGB	8.1	aL
HCT	23.7	L
MCV	84.6	
MCH	28.9	
MCHC	34.1	
RDW	15.1	
RDW-SD	43.8	
PLT	5	cL
MPV	11.0	

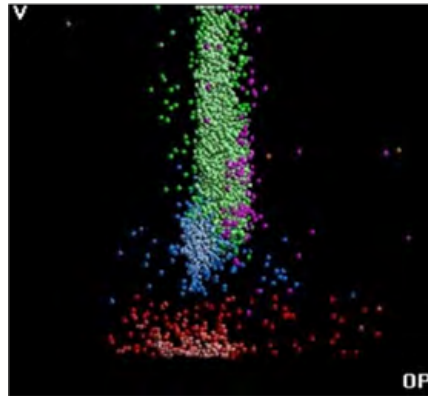
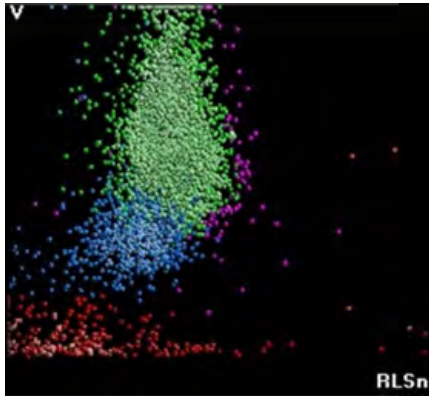


Test	Result	Flags
NE	2.0	L
LY	11.6	L
MO	86.3	aH
EO	0.1	L
BA	0.0	L
NE#	0.2	cL
LY#	1.0	
MO#	7.2	aH
EO#	0.0	
BA#	0.0	
NRBC	0.6	
NRBC#	0.05	H
MDW	36.53	

The results of the WBC automated differential show monocytosis and critical neutropenia.



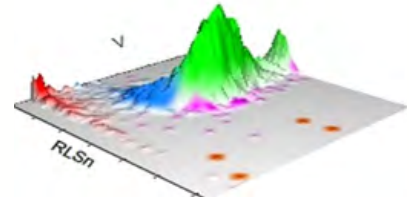
LEUKOCYTES



Suspect messages

- Imm Grans
- Left Shift
- LY Blast
- MO Blast
- Variant LY

WBC Analysis 5PD1
3D Surface plot

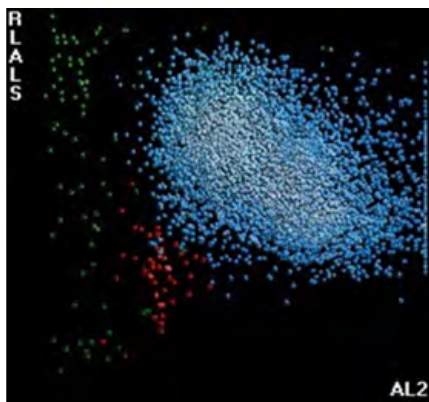


5PD1 plot (Scatter vs. Volume) and 5PD2 plot (Opacity vs. Volume) show abnormal pattern as indicated by instrument messages.

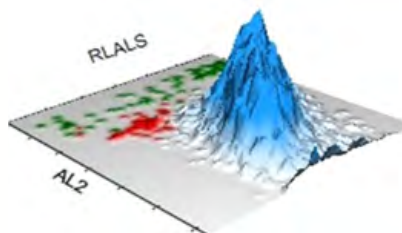
	NE		LY		MO		EO	
	Mean	SD	Mean	SD	Mean	SD	Mean	SD
V	157	51.81 ↑	103 ↑	19.54 ↑	167	32.64 ↑	158	2.00
C	144	15.03	118	11.04	127	6.88	197	40.00
MALS	120 ↓	27.53	77	19.62	99 ↑	13.10	223	13.00
UMALS	120	25.53	80	19.69	100	13.76	225	9.50
LMALS	114	32.27	68	23.14	92	16.00	218	16.00
LALS	128	55.24	41	14.82	91	34.92	195	60.00
AL2	137	33.11	83	11.51	134	18.98	155	67.00

The values of Cell Population Data show increased @NE Volume SD, decreased @NE MALS Mean, increased @LY Volume SD and increased @LY Volume Mean, increased @MO Volume SD, and increased @MO MALS Mean as compared with normal specimen.

NRBC



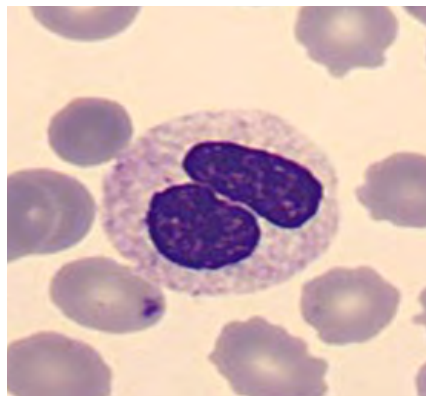
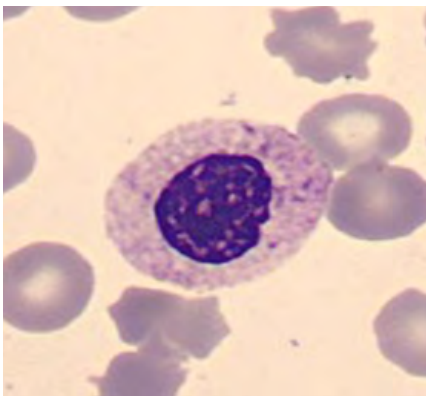
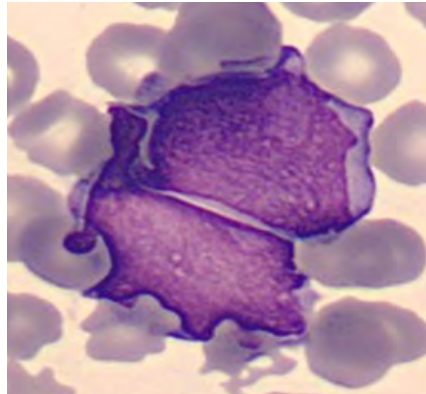
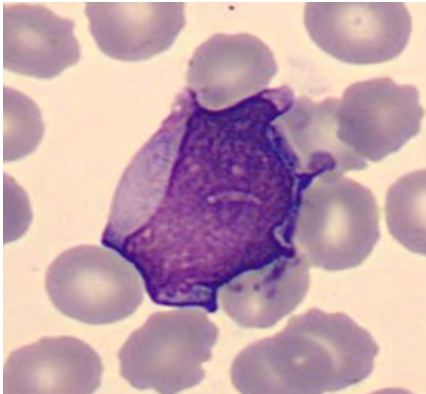
NRBC1 plot shows single WBC population and few NRBC (in red).



For research use only. Not for use in diagnostic procedures.
© - Research Use Only (RUO) parameters



BLOOD SMEAR



Manual Differential	
Neutrophils	32
Band Neutrophils	0
Lymphocytes	8
Monocytes	2
Eosinophils	0
Basophils	0
Metamyelocytes	
Myelocytes	
Promyelocytes	
Immature Granulocytes	0.5
Atypical Lymphocytes	4
Blast	53.5
NRBC	

Summary Results

- › Normal WBC count with monocytosis and severe neutropenia
- › Normocytic normochromic anemia and severe thrombocytopenia, with abnormal platelet histogram but correct platelet count reported
- › WBC histogram shows a predominant population of cells recognized as monocytes
- › 5PD1 plot (Scatter vs. Volume) and 5PD2 plot (Opacity vs. Volume) show anisocytosis of neutrophils and monocytes, decreased scatter of neutrophils and increased scatter of monocytes
- › 53.3% of blast cells observed on the blood film and degranulated neutrophils, which is compatible with decreased neutrophil scatter

DIAGNOSIS: ACUTE MYELOID LEUKEMIA



CASE 4 | ACUTE PANMYELOSIS WITH MYELOFIBROSIS

Disease Description

Acute panmyelosis with myelofibrosis is an aggressive form of de novo acute myelogenous leukemia (AML) occurring primarily in adults. It is characterized by acute panmyeloid proliferation with increased blasts, cytopenias with bone marrow fibrosis, and absence of splenomegaly.

It is rare accounting for less than 1% of the cases of acute myeloid leukemias.

Median age at diagnosis is approximately 67 years, and males are more commonly affected than females.

Accurate and timely diagnosis is critical as this disease is rapidly progressive and almost always fatal.

Excluded from consideration prior to making this diagnosis are other groups of AML such as AML with recurrent cytogenetic abnormalities, AML, myelodysplasia-related (AML-MR), and AML post-cytotoxic therapy.

Clinicopathologic Features^{1,7}

Patients present with abrupt onset of fever, bone pain, and pancytopenia. Radiologically, there is no evidence of or minimal splenomegaly.

LABORATORY FINDINGS

Peripheral Blood:

Marked pancytopenia is noted. Leukoerythroblastosis, characterized by marked anisopoikilocytosis of RBCs, the presence of dacryocytes (tear-drop shaped RBCs), nucleated red cells, and left-shifted granulocytic maturation with blasts, is conspicuously absent. Red blood cell morphology is unremarkable. Neutrophils show dysgranulopoiesis changes including the presence of pseudo-Pelger-Huët and/or hypogranulated forms. Occasional rare circulating blasts are seen. Abnormal platelets, including hypogranular, hypergranular, and giant forms, can be seen.

Bone Marrow:

Bone marrow aspiration results in a 'dry tap' due to significant fibrosis. A good bone marrow biopsy is critical for reaching the diagnosis.

Bone marrow is hypercellular with variable degrees of expansion of erythroid, myeloid, and megakaryocytic precursors. Megakaryocytes are increased with the presence of frequent micromegakaryocytes and atypical megakaryocytes with non-lobulated or hypolobulated nuclei. These are better highlighted with periodic acid-Schiff (PAS) staining or immunohistochemistry with CD61 or CD42b. Blasts are increased and often arranged into scattered aggregates and clusters highlighted by CD34 immunohistochemistry. The blast percentage is usually between 20-25%. By flow cytometry, blasts express one or more myeloid antigens (CD33, CD117). As the name signifies, diffuse and markedly increased fibrosis is a characteristic feature. Reticulin stain highlights increased diffusely coarse reticulin fibers. Collagen deposition is less common.

Genetics:

Due to dry tap, a specimen is difficult to obtain for cytogenetic studies. If successful, conventional karyotyping usually shows a complex (≥ 3 abnormalities) karyotype.

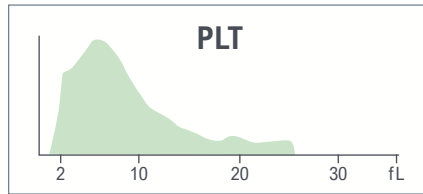
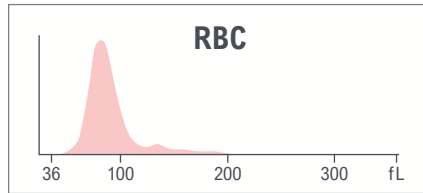
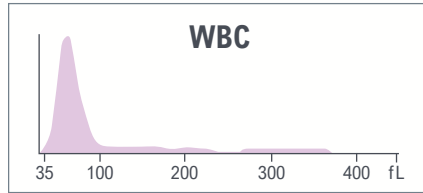
CBC parameters indicate leukopenia, normocytic normochromic anemia, and thrombocytopenia.

Abnormal WBC histogram with predominant lymphoid population.

Red indicates a critical limit is exceeded.

Yellow indicates an action limit is exceeded.

Test	Result	Flags
WBC	0.9	aL
UWBC	0.9	aL
RBC	3.04	L
HGB	9.2	L
HCT	27.2	L
MCV	89.4	
MCH	30.3	
MCHC	33.8	
RDW	15.4	
RDW-SD	45.5	
PLT	30	aL
MPV	8.6	





Test	Result	Flags
NE	22.5	L
LY	76.3	H
MO	0.3	L
EO	0.8	
BA	0.1	L
NE#	0.2	cL
LY#	0.7	L
MO#	0.0	L
EO#	0.0	
BA#	0.0	
NRBC	0.3	
NRBC#	0.00	

The results of the WBC automated differential show critical neutropenia, lymphopenia, and monocytopenia.






LEUKOCYTES



Suspect messages

- Imm Grans
- NE Blast
- Variant LY

WBC Analysis 5PD1
3D Surface plot

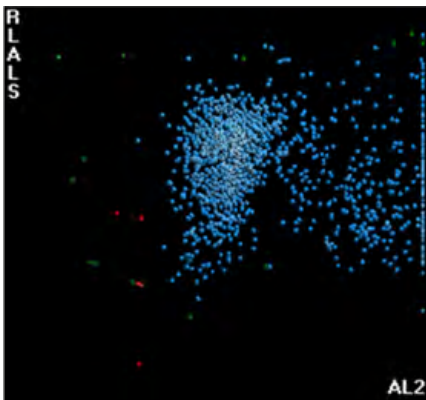


5PD1 plot (Scatter vs. Volume) and 5PD2 plot (Opacity vs. Volume) show abnormal patterns with predominant abnormal LY population and some debris.

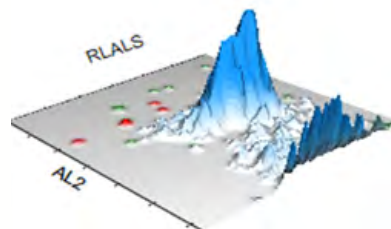
	NE		LY		MO		EO	
	Mean	SD	Mean	SD	Mean	SD	Mean	SD
V	206 ↑	43.68 ↑	86	16.57	204	41.74	182	21.88
C	130 ↓	11.01 ↑	119	6.86	115	12.93	144	10.45
MALS	102 ↓	16.37 ↑	68	19.35	58	8.42	143	20.08
UMALS	104 ↓	18.56 ↑	65	23.60	61	13.62	146	24.52
LMALS	97 ↓	16.97 ↑	64	22.01	52	9.33	137	17.72
LALS	98 ↓	31.61 ↑	36	11.84	56	21.61	162	37.24
AL2	173 ↓	36.77 ↑	83	12.58	148	35.51	163	21.28

The values of Cell Population Data show increased @NE Volume Mean and @NE Volume SD, decreased @NE Conductivity Mean, increased @NE Conductivity SD, decreased all @NE Scatter Mean, and increased all @NE Scatter SD as compared with normal specimen.

NRBC

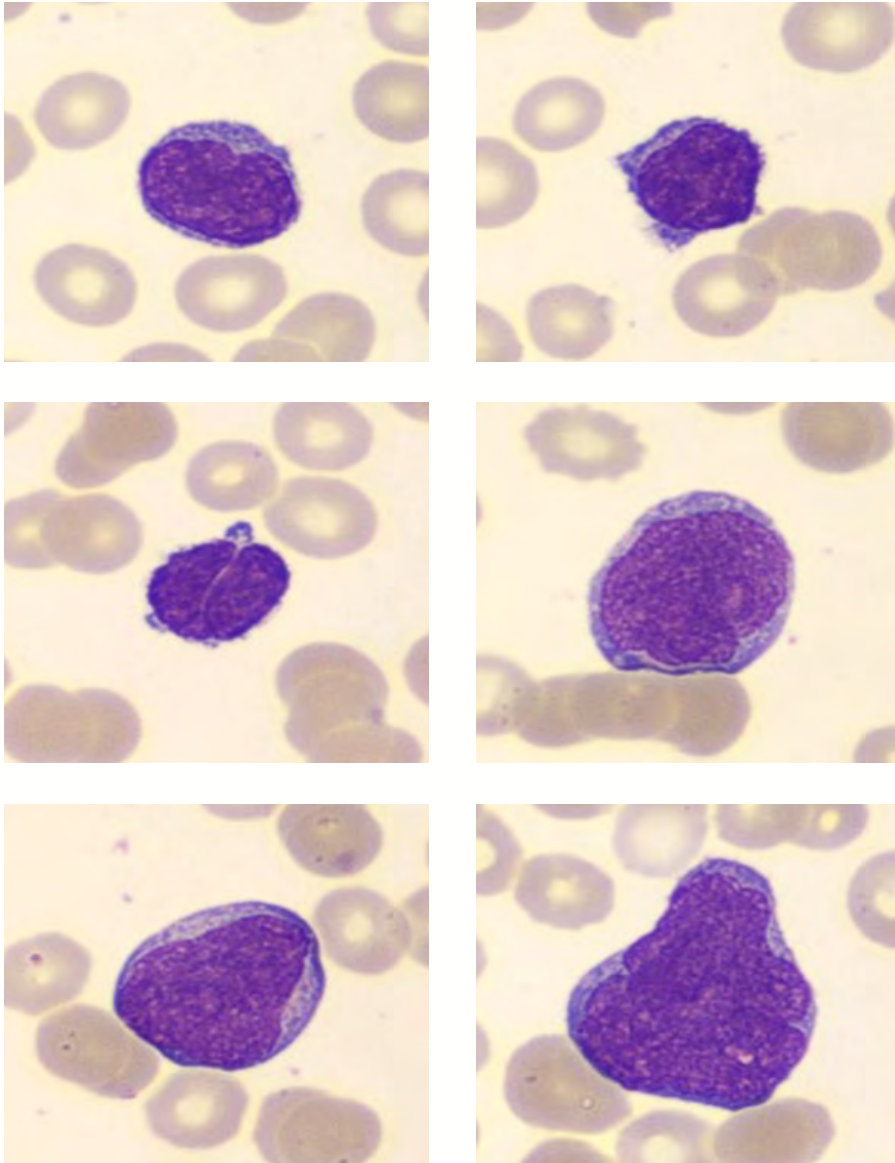


NRBC1 plot shows abnormal pattern with predominant lymphoid population.



For research use only. Not for use in diagnostic procedures.
@ - Research Use Only (RUO) parameters

BLOOD SMEAR



Manual Differential	
Neutrophils	4
Band Neutrophils	
Lymphocytes	74
Monocytes	0
Eosinophils	0
Basophils	0
Metamyelocytes	
Myelocytes	
Promyelocytes	
Immature Granulocytes	
Atypical Lymphocytes	
Blast	22
NRBC	

Comments:

While the manual differential count shows 22% blasts, which is compatible with the diagnosis of acute leukemia, because of significant myelofibrosis in the marrow in a typical case of APMF, it is uncommon to see a significant number of blasts in the peripheral blood.

Summary Results

- › Normocytic normochromic anemia and thrombocytopenia
- › Leukopenia with severe neutropenia, lymphopenia and monocytopenia. Abnormal WBC histogram with predominant lymphoid population
- › 5PD1 plot (Scatter vs. Volume) and 5PD2 plot (Opacity vs. Volume) show abnormal patterns with predominant abnormal LY
- › NRBC1 plot shows abnormal pattern with predominant lymphoid population
- › Blood film shows 22% blast cells. The blast cells are large, with a high nucleocytoplasmic ratio and no Auer rods observed in the cytoplasm

DIAGNOSIS: ACUTE PANMYELOSIS WITH MYELOFIBROSIS





CASE 5 | ACUTE MONOCYTC LEUKEMIA

Disease Description

Excluded from consideration prior to making this diagnosis are other groups of AML such as AML with recurrent cytogenetic abnormalities, AML, myelodysplasia-related (AML-MR), and AML post-cytotoxic therapy.

In the 5th edition of the WHO Classification of Tumors of Hematopoietic and Lymphoid Tissues, acute monocytic leukemia is defined by $\geq 80\%$ monocytes and/or their precursors (monoblasts and/or promonocytes) and $< 20\%$ maturing granulocytic cells in peripheral blood or bone marrow.²

Blasts and promonocytes express at least two monocytic markers including CD11c, CD14, CD36 and CD64, as demonstrated by flow cytometry and/or immunohistochemistry, or non-specific esterase (NSE) positivity on cytochemistry.

Acute monocytic leukemia is rare, accounting for less than 5% of all AML cases.

Clinicopathologic Features^{1,2}

Patients with acute monocytic leukemia present with extramedullary masses, and skin and gingival infiltration. They often show coagulation abnormalities including disseminated intravascular coagulation. Central nervous system involvement is common.

LABORATORY FINDINGS

Patients frequently present with hyperleukocytosis. The median WBC count is $30 \times 10^9/L$ (range, 1.3 to $178.0 \times 10^9/L$).

Normocytic normochromic anemia and thrombocytopenia are common (80% of cases).

PERIPHERAL BLOOD AND BONE MARROW FINDINGS

Bone marrow biopsy is hypercellular for age and shows sheets of large immature mononuclear cells with rounded nuclei, finely dispersed chromatin, prominent nucleoli, and abundant cytoplasm.

Overall, 80% or more of all nucleated cells are of monocytic origin, with 20% or more of all nucleated cells consisting of myeloblasts, monoblasts, or promonocytes.

Monoblasts are typically large blasts with large, round nuclei showing delicate, lacy chromatin and one or more prominent nucleoli. They have abundant cytoplasm that is moderately basophilic and may contain scattered fine granules and sometimes vacuoles.

Promonocytes are equally large cells with delicate, lacy chromatin, however, the nucleus demonstrates a delicately folded, or grooved appearance. Nucleoli are present and their cytoplasm is finely granulated and with varying proportions of granules and/or vacuoles.

Hemophagocytosis is commonly encountered in bone marrow aspirate smears.

Cytochemical staining for NSE shows strong positivity in monoblasts and promonocytes.

Myeloperoxidase is negative in monoblasts and weakly positive in promonocytes.

Flow cytometric immunophenotyping is useful to establish monocytic lineage. Monoblasts and promonocytes are CD34-, CD117-/+ and show expression of two or more markers of monocytic differentiation including CD14, CD4, CD11b, CD11c, CD36, and CD64.

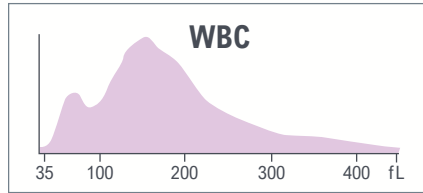
CBC parameters indicate leukocytosis and macrocytic anemia with anisocytosis.

Abnormal WBC histogram with peak in the area between 100 fL and 200 fL.

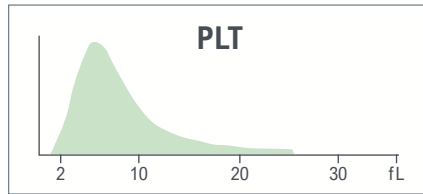
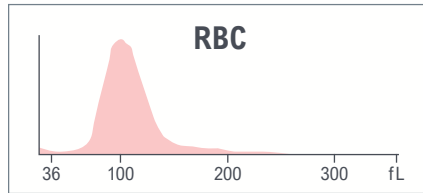
Red indicates a critical limit is exceeded.

Yellow indicates an action limit is exceeded.

Test	Result	Flags
WBC	66.6	cH
UWBC	66.6	cH
RBC	2.32	L
HGB	7.9	aL
HCT	24.5	L
MCV	105.6	aH
MCH	34.2	aH
MCHC	34.4	L
RDW	19.0	H
RDW-SD	66.9	H
PLT	251	
MPV	8.6	



System messages
 • Abn Diff Pattern

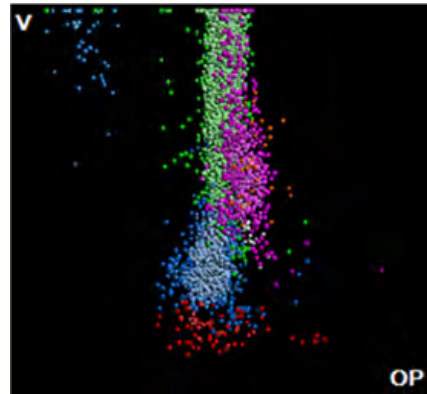



Test	Result	Flags
NE	7.7	R L
LY	20.9	R
MO	70.4	R aH
EO	0.4	R L
BA	0.6	R
NE#	5.1	R
LY#	13.9	R aH
MO#	46.9	R aH
EO#	0.2	R
BA#	0.4	R H
NRBC	0.0	
NRBC#	0.00	

The results of the WBC automated differential flagged with R for review due to the presence of system message, Abn Diff Pattern.



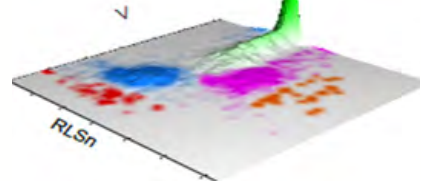
LEUKOCYTES



Suspect messages

- Imm Grans
- Left Shift
- MO Blast

WBC Analysis 5PD1
3D Surface plot



5PD1 plot (Scatter vs. Volume) and 5PD2 plot (Opacity vs. Volume) show abnormal pattern as indicated by instrument message.

	NE		LY		MO		EO	
	Mean	SD	Mean	SD	Mean	SD	Mean	SD
V	157	35.99 ↑	104 ↑	49.68 ↑	215 ↑	36.36 ↑	152	24.54
C	141	8.58	119	14.77	130	5.82	148	9.36
MALS	140	17.16	73	21.47 ↑	93	11.31	193	13.76
UMALS	146	20.95	75	27.00	104	11.92	206	14.44
LMALS	130	16.39	66	22.19	79	15.26	177	14.58
LALS	135	34.47	35	11.66	96	23.13	151	49.35
AL2	154	23.60	85	12.44	170	22.87	144	20.62


The values of Cell Population Data show increased @NE Volume SD, increased @MO Volume Mean, increased @MO Volume SD, increased @LY Volume Mean, increased @LY Volume SD, increased @LY Scatter SD as compared with normal specimen.

For research use only. Not for use in diagnostic procedures.
 @ - Research Use Only (RUO) parameters

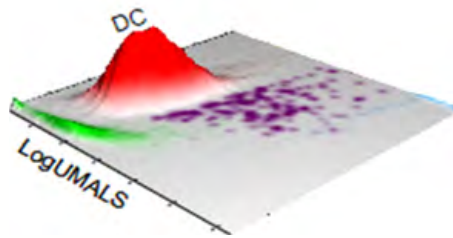




AUTOMATED RETICULOCYTE ANALYSIS

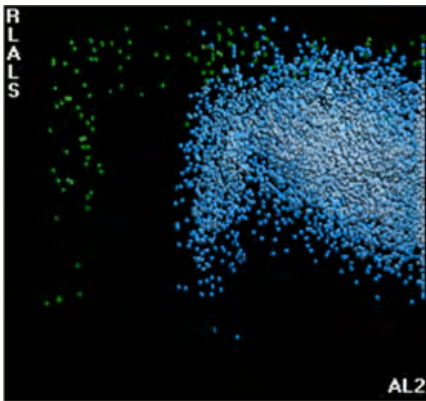


Low Retic, high MRV and high IRF. Blue population corresponds to low volume or fragile WBC.

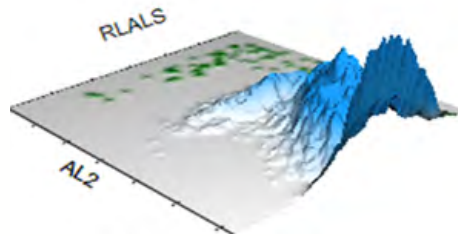


Test	Result	Flags
RET	0.54	
RET#	0.0126	L
MRV	145.7	H
IRF	0.56	H

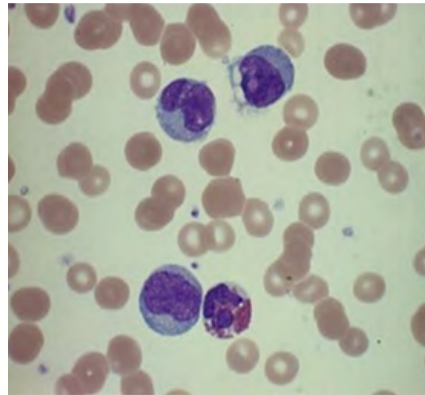
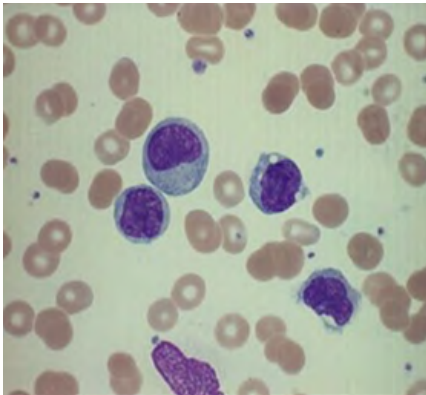
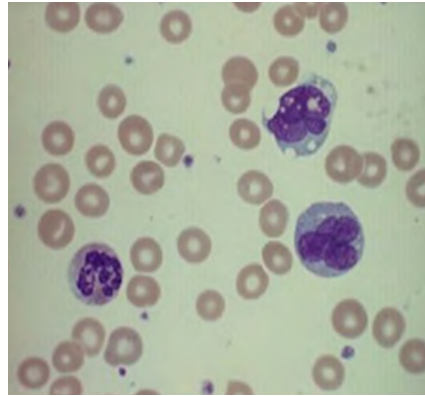
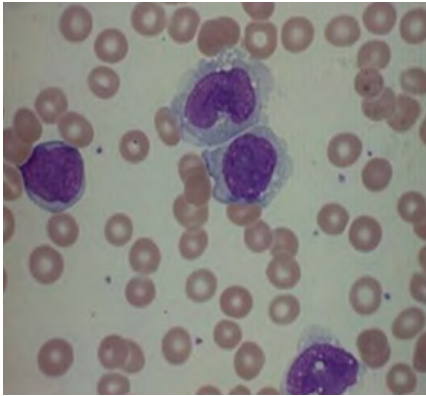
NRBC



NRBC1 plot shows abnormal pattern with predominant population of abnormal cells due to the elevated percentage of monocytic cells and monoblasts.



BLOOD SMEAR



Manual Differential	
Neutrophils	9
Band Neutrophils	0
Lymphocytes	18
Monocytes	63
Eosinophils	1
Basophils	1
Metamyelocytes	
Myelocytes	
Promyelocytes	
Immature Granulocytes	
Atypical Lymphocytes	
Blast	8
NRBC	

Comments:

The final categorization of AML rests upon ancillary studies to evaluate for recurring cytogenetic abnormalities or certain mutations. Morphologically defined categories are used only after exclusion of genetically defined AMLs.

Summary Results

- › Macrocytic anemia with anisocytosis, low Retic, high MRV and high IRF
- › Platelet count and platelet histogram appear normal
- › Leukocytosis, abnormal WBC histogram with the peak in the area of mononuclear cells and abnormal diff pattern on 5PD1 plot (Scatter vs. Volume) and 5PD2 plot (Opacity vs. Volume)
- › 63% of monocytes and 8% of blasts observed on blood film

DIAGNOSIS: ACUTE MONOCYTIC LEUKEMIA





CASE 6 | ACUTE MYELOID LEUKEMIA-M2 AT RELAPSE

Disease Description

Acute Myeloid Leukemia (AML) is the most common form of acute leukemia in adults. Genetic damage results in an increased rate of proliferation, reduced apoptosis, and a block in cellular differentiation.

Acute myeloid leukemia with maturation (AML-M2) is characterized by the presence of $\geq 20\%$ blasts in the bone marrow and evidence of maturation ($\geq 10\%$ maturing cells of neutrophil lineage). AML-M2 comprises 10% of cases of AML. It occurs in all age groups; 20% of patients are < 25 years of age, and 40% are ≥ 60 years of age.

Clinicopathologic Features^{1,2}

Bone marrow failure is caused by the accumulation of malignant cells within the marrow. Patients typically present with fever and fatigue, and infections are frequent. Anemia and thrombocytopenia are often profound.

LABORATORY FINDINGS

The blood or bone marrow have $> 20\%$ blasts, however, AML-M2 can be diagnosed with less than 20% blasts if specific leukemia-associated cytogenetic or molecular genetic abnormalities are present.

The lineage of the blast cells is defined by microscopic examination (morphology), immunophenotypic (flow cytometry), and cytogenetic and molecular analyses. Patients show normocytic normochromic anemia with variable WBC count.

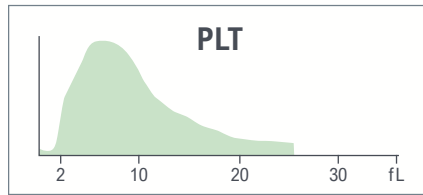
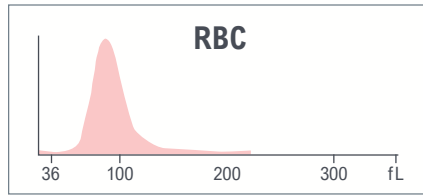
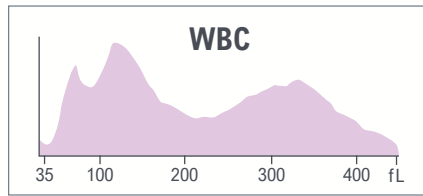
NOTE: The final categorization of acute myeloid leukemia rests upon ancillary studies to evaluate for recurring cytogenetic abnormalities or certain mutations. Morphologically defined categorization is done only after the exclusion of genetically defined acute myeloid leukemias.

CBC parameters indicate leukopenia, normocytic normochromic anemia with anisocytosis, and thrombocytopenia.

Abnormal WBC histogram with an elevated area between 100 and 200 fL.

Yellow indicates an action limit is exceeded.

Test	Result	Flags
WBC	2.2	L
UWBC	2.2	L
RBC	2.81	L
HGB	8.6	L
HCT	25.7	L
MCV	91.4	
MCH	30.4	
MCHC	33.3	
RDW	16.4	H
RDW-SD	51.6	H
PLT	76	L
MPV	9.6	



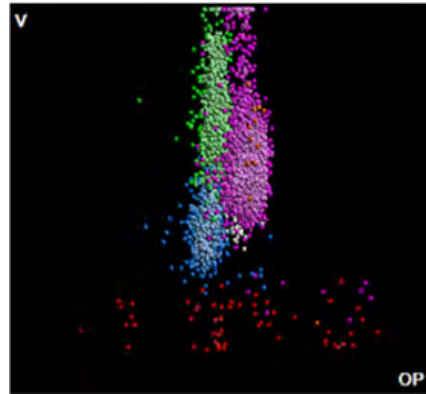

Test	Result	Flags
NE	54.1	
LY	11.1	L
MO	29.8	H
EO	0.2	L
BA	4.8	aH
NE#	1.2	L
LY#	0.2	L
MO#	0.6	
EO#	0.0	
BA#	0.1	
NRBC	0.4	
NRBC#	0.01	

The results of the WBC automated differential show neutropenia, lymphopenia, and basophilia.





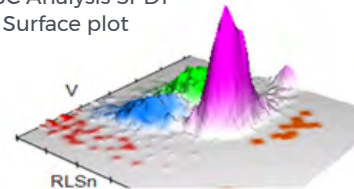
LEUKOCYTES



Suspect messages

- Imm Grans
- Left Shift
- MO Blast
- NE Blast

WBC Analysis 5PD1
3D Surface plot




5PD1 plot (Scatter vs. Volume) and 5PD2 plot (Opacity vs. Volume) show abnormal patterns as indicated by instrument messages.

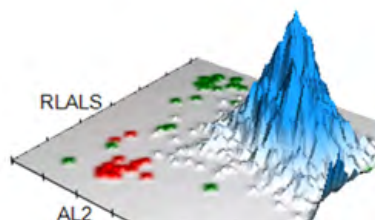
	NE		LY		MO		EO	
	Mean	SD	Mean	SD	Mean	SD	Mean	SD
V	153	25.80 ↑	109 ↑	15.94	180	24.57 ↑	172	20.91
C	146	5.80	120	6.68	125	4.60	148	3.05
MALS	134	10.90	64	18.36	73 ↓	15.61	192	6.31
UMALS	132	15.41	66	22.04	85	14.81	203	7.20
LMALS	130	12.86	55	20.60	59	19.89	177	10.88
LALS	151	33.87	42	12.80	56	27.50	118	26.26
AL2	158	17.59	107	11.87	154	14.69	150	7.54

The values of Cell Population Data show increased @NE Volume SD, increased @MO Volume SD, increased @LY Volume Mean, and decreased @MO MALS Mean as compared with normal specimen.

NRBC

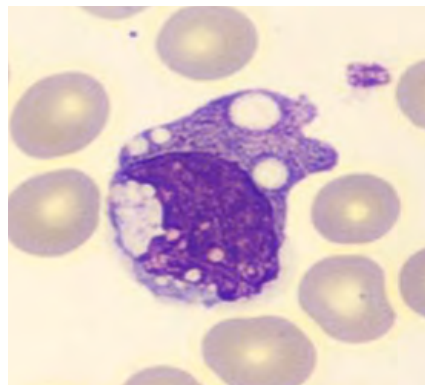
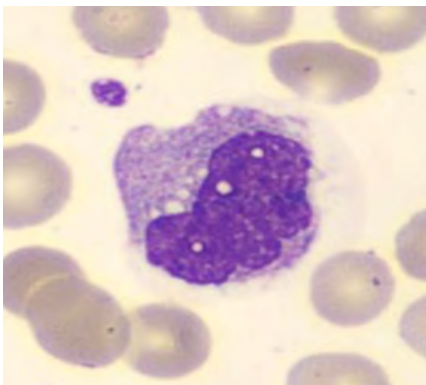
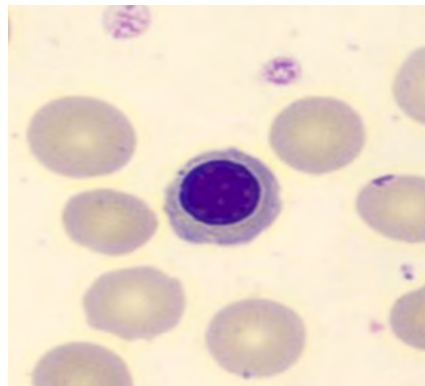
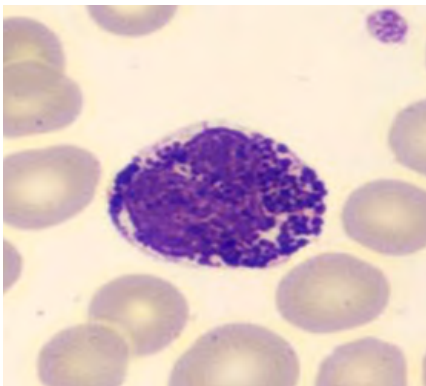
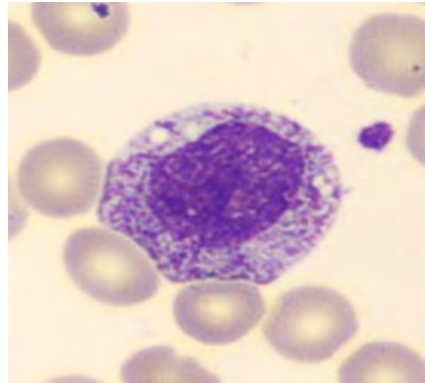
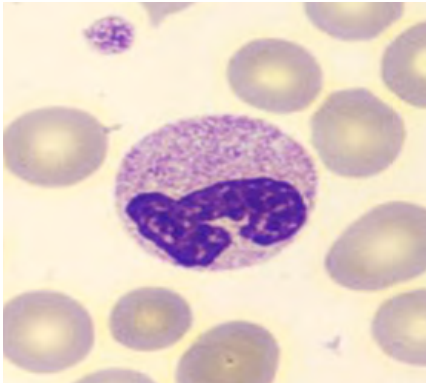


NRBC1 plot shows a scarce subpopulation of lymphocyte nuclei and a clear predominance of neutrophil and monocyte nuclei.



For research use only. Not for use in diagnostic procedures.
@ - Research Use Only (RUO) parameters

BLOOD SMEAR



Manual Differential	
Neutrophils	41
Band Neutrophils	
Lymphocytes	11
Monocytes	32
Eosinophils	0
Basophils	6
Metamyelocytes	
Myelocytes	
Promyelocytes	
Immature Granulocytes	10
Atypical Lymphocytes	
Blast	
NRBC	

Summary Results

- › Normocytic normochromic anemia with anisocytosis
- › Thrombocytopenia
- › Leukopenia with neutropenia, lymphopenia and basophilia, anisocytosis of neutrophils and monocytes, abnormal scatter of monocytes
- › 10% Immature Granulocytes observed on the blood film

DIAGNOSIS: ACUTE MYELOID LEUKEMIA-M2 AT RELAPSE





CASE 7 | ACUTE MYELOID LEUKEMIA AT DIAGNOSIS

Disease Description

Acute myeloid leukemia (AML) is a malignancy of hematopoietic stem cell precursors arising in the bone marrow and causing bone marrow failure. The disease is associated with qualitative and quantitative abnormalities of hematopoietic cells in peripheral blood and bone marrow. While AML accounts for only 1.2% of all newly diagnosed cancer cases in the United States per year, it accounts for 15-20% and 35% of leukemias in children and adults respectively.⁸

One hallmark of AML is simultaneous proliferation and apoptosis of hematopoietic cells leading to cellular proliferation in the marrow but peripheral pancytopenia. Impaired hematopoiesis leads to dysfunctional neutrophils, monocytes, and platelets.

AML diagnosis is established by the presence of 20% or more myeloid blasts in peripheral blood or bone marrow aspirates, but in the context of certain recurrent genetic abnormalities, e.g., t [t(8;21), inv(16), or t(15;17)], the blast count is irrelevant and the latter cases are diagnosed regardless of the percentage of blasts in the blood or bone marrow.⁹

Clinicopathologic features^{1,2}

While some patients will be diagnosed on routine blood work, most patients present with a myriad of signs and symptoms secondary to ineffective erythropoiesis or bone marrow failure. Patients commonly present with recurrent infections, anemia, bruising, bleeding from gums or other mucosal sites, and disseminated intravascular coagulation.

Severe anemia can manifest in the form of easy fatiguability, shortness of breath, and generalized weakness. Organ infiltration by leukemic cells is common and can manifest in the form of hepatosplenomegaly, skin rashes, and rarely lymphadenopathy.

LABORATORY FINDINGS

Pancytopenia is a common feature. Peripheral blood may show features of disseminated intravascular coagulation, which includes the presence of schistocytes and polychromasia. Blasts are often present and can vary from occasional to greater than 20%. In cases where the blasts are $\geq 20\%$, diagnosis of acute myeloid leukemia can be made using peripheral blood.

Maturing myeloid cells such as granulocytes often display dysplastic features including pseudo-Pelger-Huët anomaly, hypogranular cytoplasm, or abnormal inclusions. Platelets can show giant and hypogranular forms.

NOTE: The final categorization of acute myeloid leukemia rests upon ancillary studies to evaluate for recurring cytogenetic abnormalities or certain mutations. Morphologically defined categorization is done only after the exclusion of genetically defined acute myeloid leukemias.

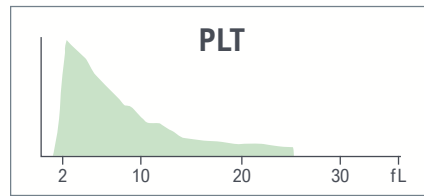
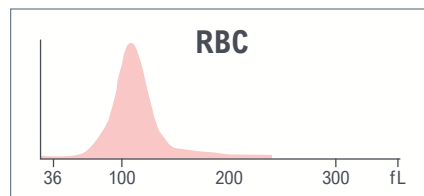
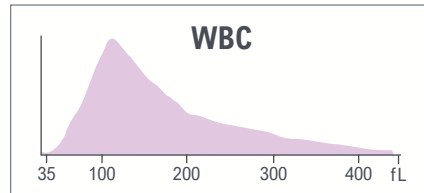
CBC parameters indicate leukocytosis and macrocytic hyperchromic anemia with anisocytosis and thrombocytopenia.

An abnormal WBC histogram shows a single population of cells with an extension on the right side.

Red indicates a critical limit is exceeded.

Yellow indicates an action limit is exceeded.

Test	Result	Flags
WBC	108.6	cH
UWBC	108.6	cH
RBC	2.30	L
HGB	8.3	aL
HCT	26.4	L
MCV	114.6	aH
MCH	36.3	aH
MCHC	31.6	L
RDW	15.6	
RDW-SD	60.4	H
PLT	19	cL
MPV	8.5	



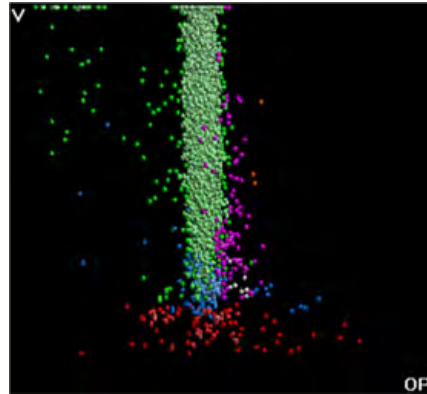
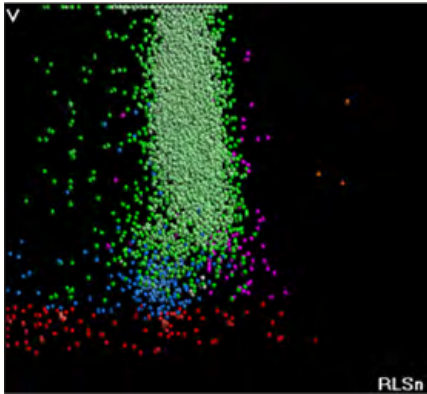
Test	Result	Flags
NE	1.3	L
LY	2.6	L
MO	96.0	aH
EO	0.0	L
BA	0.1	L
NE#	1.4	L
LY#	2.8	
MO#	104.2	aH
EO#	0.0	
BA#	0.1	
NRBC	0.0	
NRBC#	0.04	H

The results of the WBC automated differential show neutropenia and monocytosis.





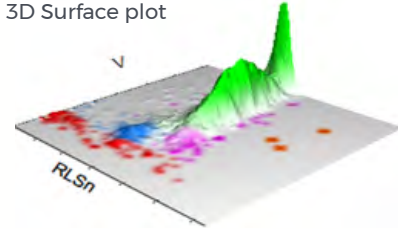
LEUKOCYTES



Suspect messages

- Imm Gran
- Left Shift
- LY Blast
- MO Blast

WBC Analysis 5PD1
3D Surface plot




5PD1 plot (Scatter vs. Volume) and 5PD2 plot (Opacity vs. Volume) show abnormal patterns as indicated by multiple instrument messages with single predominant population of cells classified as monocytes.

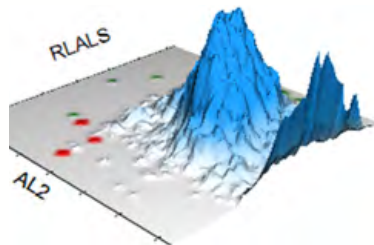
	NE		LY		MO		EO	
	Mean	SD	Mean	SD	Mean	SD	Mean	SD
V	116	42.17	77	22.16	184 ▲	43.29 ▲	158	24.17
C	133	7.02	119	14.69	116 ▼	7.55	149	2.16
MALS	131	21.36	87	23.10	109 ▲	13.23	202	7.87
UMALS	137	20.68	91	20.70	115	22.76	219	11.61
LMALS	119	25.64	79	26.51	97	17.40	179	5.19
LALS	76	34.93	26	7.29	73	24.74	156	14.61
AL2	116	26.87	55	7.89	112	25.78	142	25.20

The values of Cell Population Data show increased @MO Volume Mean, @MO Volume SD, and @MO MALS Mean and decreased @MO Conductivity Mean as compared with normal specimen.

NRBC



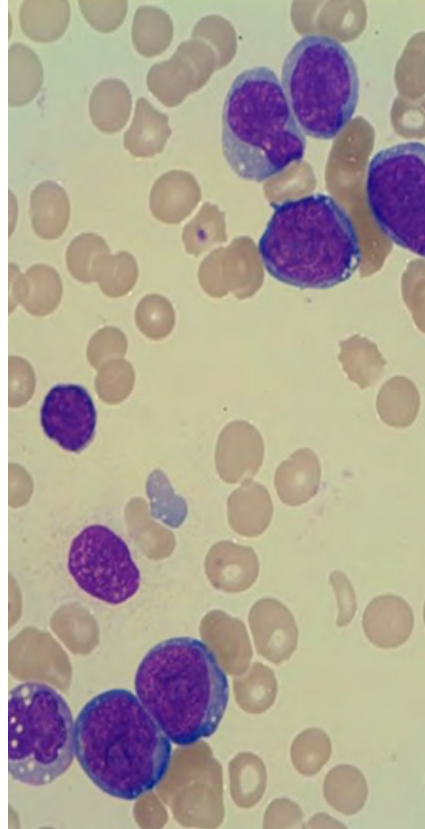
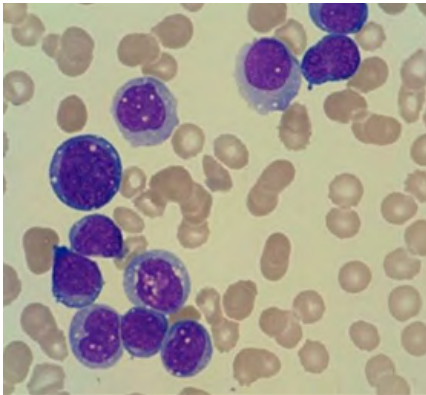
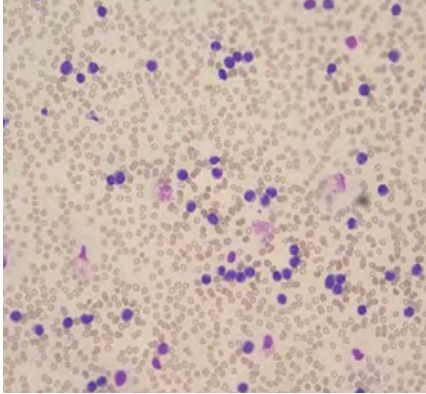
NRBC1 plot shows one predominant population of cells.



For research use only. Not for use in diagnostic procedures.

@ - Research Use Only (RUO) parameters

BLOOD SMEAR



Manual Differential	
Neutrophils	0.5
Band Neutrophils	
Lymphocytes	6
Monocytes	59
Eosinophils	0
Basophils	0
Metamyelocytes	
Myelocytes	
Promyelocytes	
Immature Granulocytes	
Atypical Lymphocytes	
Blast	34.5
NRBC	

Summary Results

- > Macrocytic hyperchromic anemia with anisocytosis
- > Thrombocytopenia
- > Leukocytosis with neutropenia and monocytosis
- > Predominant population of abnormal cells classified as monocytes on WBC Analysis 5PD1 3D Surface plot
- > Macrocytosis and anisocytosis, increased scatter, and decreased conductivity of these abnormal cells as compared with monocytes from normal specimen on WBC Analysis 5PD1 3D Surface plot
- > Cells with large nuclei are seen on the blood film. Also, abnormal monocytes with irregular nuclei, abundant cytoplasmic vacuoles, and several cells with morphology of blasts observed on blood

DIAGNOSIS: ACUTE MYELOID LEUKEMIA AT DIAGNOSIS





1. WHO Classification of Tumours Editorial Board, Campo E, Harris NL, et al. *WHO Classification of Tumours of Haematopoietic and Lymphoid Tissues (Medicine)*. Revised. World Health Organization; 2017:585.
2. Khoury JD, Solary E, Abla O, et al. The 5th edition of the World Health Organization Classification of Haematolymphoid Tumours: Myeloid and Histiocytic/Dendritic Neoplasms. *Leukemia*. 2022;36(7):1703-1719. doi:10.1038/s41375-022-01613-1.
3. Greenberg PL, Tuechler H, Schanz J, et al. Revised international prognostic scoring system for myelodysplastic syndromes. *Blood*. 2012;120(12):2454-2465. doi:10.1182/blood-2012-03-420489.
4. Schanz J, Tüchler H, Solé F, et al. New comprehensive cytogenetic scoring system for primary myelodysplastic syndromes (MDS) and oligoblastic acute myeloid leukemia after MDS derived from an international database merge. *J Clin Oncol*. 2012;30(8):820-829. doi:10.1200/JCO.2011.35.6394. /
5. Creutzig U, van den Heuvel-Eibrink MM, Gibson B, et al. Diagnosis and management of acute myeloid leukemia in children and adolescents: recommendations from an international expert panel. *Blood*. 2012;120(16):3187-3205. doi:10.1182/blood-2012-03-362608.
6. Döhner H, Estey E, Grimwade D, et al. Diagnosis and management of AML in adults: 2017 ELN recommendations from an international expert panel. *Blood*. 2017;129(4):424-447. doi:10.1182/blood-2016-08-733196.
7. Orazi A, O'Malley DP, Jiang J, et al. Acute panmyelosis with myelofibrosis: an entity distinct from acute megakaryoblastic leukemia. *Mod Pathol*. 2005;18(5):603-614. doi:10.1038/modpathol.3800348.
8. Creutzig U, van den Heuvel-Eibrink MM, Gibson B, Dworzak MN, et al. Committee of the International BFM Study Group. Diagnosis and Management of Acute Myeloid Leukemia in Children and Adolescents: Recommendations from an International Expert Panel. *Blood*. 2012;120(16):3187-205.
9. Döhner H, Estey E, Grimwade D, et al. Diagnosis and Management of AML in Adults: 2017 ELN Recommendations from an International Expert Panel. *Blood*. 2017;129(4):424-47.



Red Blood Cell Disorders

Case 1	Beta Thalassemia Trait
Case 2	Hemoglobin SS/ Sickle Cell Anemia Disease
Case 3	Sickle Cell Trait
Case 4	Vitamin B12 Deficiency
Case 5	Iron Deficiency Anemia with Platelet Clumps



CASE 1 | BETA THALASSEMIA TRAIT

Disease Description

The term “thalassemia,” which simply refers to decreased production of usually normal hemoglobin molecules, originates from the Greek “thalassa” for “sea” and was coined in 1925 by Dr. Thomas Cooley and his colleague Dr. Pearl Lee describing pediatric cases that presented with severe anemia.

Beta-thalassemia occurs due to decreased production of beta-globin genes residing on chromosome 11. It is caused by a single mutation in the genes or chromosomal regions that control beta-gene production. To date, over 200 mutations are known to occur.

β^+ mutations result in a reduced (but not absent) production from the affected beta gene(s), while in β^0 mutations, there is complete absence of production from the affected allele. Patients with complete absence of beta-globin gene production, β^0/β^0 , have the most severe form of the disease, beta-thalassemia major, which requires life-long blood transfusions. Patients with the beta-thalassemia trait usually have β/β^+ or the β/β^0 genotype, resulting in decreased production of beta-globin genes and more moderate anemia.

Clinicopathologic Features

Clinically, patients with the beta-thalassemia trait are asymptomatic because production of beta-globin is unaffected due to the presence of one normal gene. Even though they may be asymptomatic, these patients may manifest several hematologic abnormalities including low MCV, low MCHC, high RBC count ($>5.5 \times 10^6/\mu\text{L}$), and mild anemia (10–12 g/dL) with microcytic and hypochromic RBCs.

Hemoglobin electrophoresis characteristically shows raised HbA₂, typically between 4–8% with a mean of about 5–6%. A caveat in solely using elevated HbA₂ for diagnosis is the presence of concurrent iron deficiency, which can lead to suppression and thus mask the elevation of HbA₂. Hence, it is always prudent to assess for iron deficiency prior to diagnosis of thalassemia. If iron deficiency is detected, hemoglobin electrophoresis should be performed and interpreted only after adequate iron supplementation.

Those with the beta-thalassemia trait will also show elevated hemoglobin F on Hb electrophoresis. HbF is usually in the range of 5–7% of total hemoglobin.

One of the most important indications for making the diagnosis is that it allows the possibility of prenatal counseling to patients with a partner who also has a significant Hb disorder. If both carry β -thalassemia trait, there is a 25% risk of having a child with beta-thalassemia major.



CBC parameters indicate microcytic hypochromic anemia with anisocytosis and thrombocytosis.

RBC histogram shows an abnormal pattern with a dimorphic RBC population as indicated by the instrument message “Dimorphic Reds.”

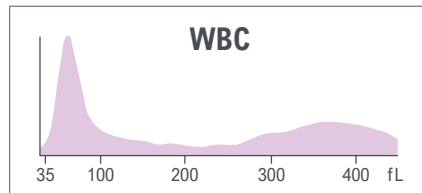
Abnormal PLT histogram with elevation in the right part and elevation in the left part of RBC histogram due to overlap between platelets and microcytic RBC.

Despite severe microcytosis, the DxH 900 algorithm can eliminate the interference and report PLT count without the R flag.

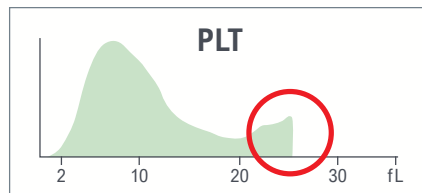
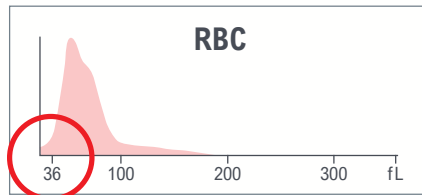
Red indicates a critical limit is exceeded.

Yellow indicates an action limit is exceeded.

Test	Result	Flags
WBC	9.4	
UWBC	9.4	
RBC	5.09	
HGB	10.3	L
HCT	32.6	L
MCV	64.1	cL
MCH	20.2	L
MCHC	31.5	L
RDW	26.5	aH
RDW-SD	55.6	H
PLT	471	H
MPV	9.9	





System messages
• Dimorphic Reds



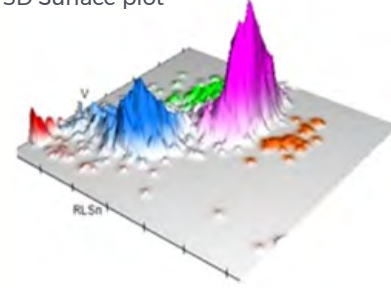
Test	Result	Flags
NE	53.9	
LY	35.8	
MO	7.4	
EO	1.0	
BA	1.9	H
NE#	5.1	
LY#	3.4	H
MO#	0.7	
EO#	0.1	
BA#	0.2	H
NRBC	0.0	
NRBC#	0.00	

Results of the WBC automated differential indicate lymphocytosis and basophilia.

LEUKOCYTES



WBC Analysis 5PD1
3D Surface plot



5PD1 plot (Scatter vs. Volume) and 5PD2 plot (Opacity vs. Volume) show abnormal pattern with large variation of LY scatter.

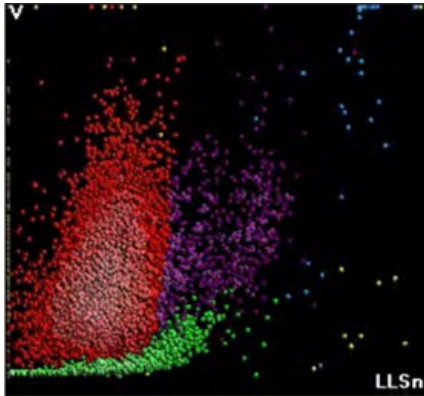
	NE		LY		MO		EO	
	Mean	SD	Mean	SD	Mean	SD	Mean	SD
V	172	23.06	91	16.31	183	20.83	171	21.97
C	152	5.85	124	13.01	133	9.22	155	4.33
MALS	134	12.71	70	23.50 ▲	85	14.58	188	9.51
UMALS	137	11.50	78	26.13	97	16.08	202	8.84
LMALS	127	17.91	58	24.37	68	18.58	170	11.44
LALS	194	46.47	36	12.23	74	27.30	198	30.80
AL2	151	14.00	68	11.82	121	15.72	135	12.02

The values of Cell Population Data show increased @LY Scatter SD as compared with normal specimen.

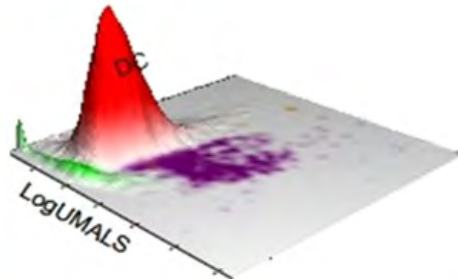
For research use only. Not for use in diagnostic procedures.
@ - Research Use Only (RUO) parameters



AUTOMATED RETICULOCYTE ANALYSIS

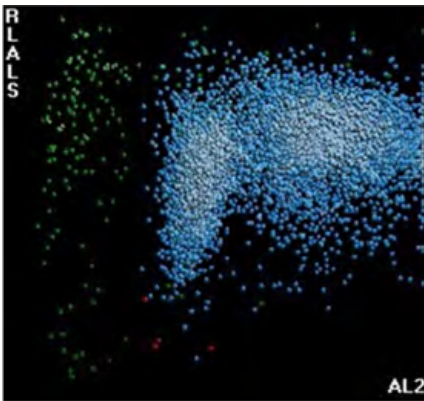


Low MRV.

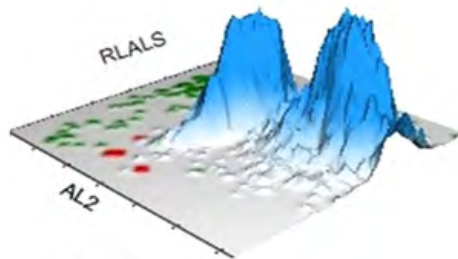


Test	Result	Flags
RET	2.10	
RET#	0.1067	
MRV	97.1	L
IRF	0.49	

NRBC



NRBC1 plot does not show any abnormalities.



Benign Categories

Lymphoid Neoplasms

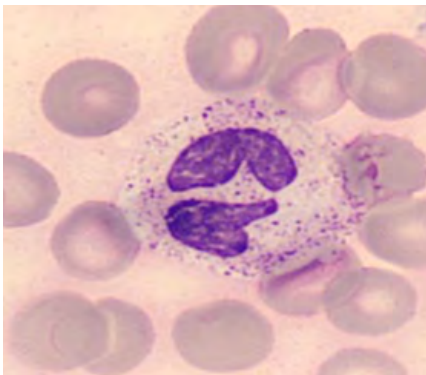
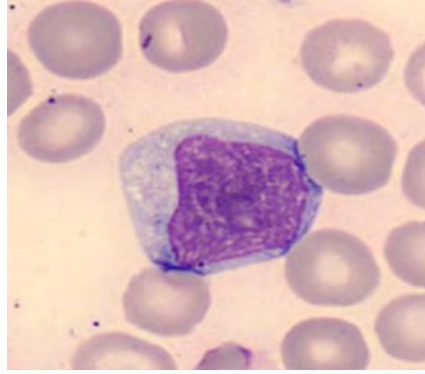
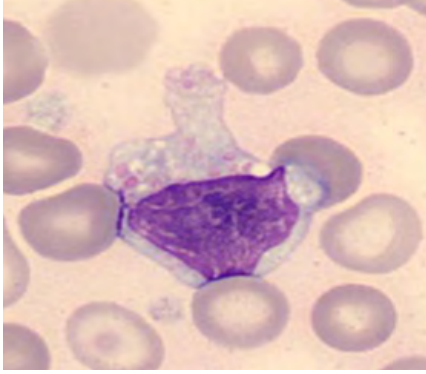
Myeloid Neoplasms/
Myelodysplastic Syndromes

Red Blood Cell Disorders





BLOOD SMEAR



Manual Differential	
Neutrophils	45
Band Neutrophils	2
Lymphocytes	7
Monocytes	7
Eosinophils	2
Basophils	1
Metamyelocytes	
Myelocytes	
Promyelocytes	
Immature Granulocytes	
Atypical Lymphocytes	36
Blast	
NRBC	

Comments:

The patient has lymphocytosis, which warrants further evaluation to determine whether this is reactive or secondary to a lymphoproliferative disorder. Peripheral blood flow cytometry and/or clonality analysis by PCR may be necessary.

Summary Results

- > Microcytic hypochromic anemia with anisocytosis, abnormal RBC histogram with dimorphic RBC population, low MRV
- > Thrombocytosis with abnormal PLT histogram due to the presence of microcytic RBC
- > Normal WBC count with lymphocytosis and basophilia; aniso-granularity of lymphocytes
- > 5PD1 plot (Scatter vs. Volume) and 5PD2 plot (Opacity vs. Volume) show abnormal LY pattern and increased @LY Scatter SD
- > Hgb electrophoresis: High Hgb F

DIAGNOSIS: BETA-THALASSEMIA TRAIT





CASE 2 | HEMOGLOBIN SS/ SICKLE CELL ANEMIA DISEASE

Disease Description

Hemoglobin SS, also known as sickle cell disease, is caused by sickle hemoglobin (HbS) resulting from mutation in the beta-globin gene. Sickle hemoglobin (HbS:α2β2s) is caused by an adenine (A) to thymidine (T) substitution (GAG to GTC) in codon 6 of the β-globin gene. The altered hemoglobin produces a defective and unstable beta-chain peptide with a single amino acid substitution (Valine to Glutamic acid) at the sixth position in the polypeptide chain. Inheritance of both mutated globin genes leads to HBSS/sickle cell anemia/disease.

Under conditions that can produce hypoxia (dehydration, high altitude, infection), this unstable beta-chain tends to polymerize and precipitate, thus distorting the shape of the RBCs to form the characteristic 'sickle' shape.

The distorted RBCs occlude small blood vessels leading to vascular occlusion crisis and hemolysis, the main processes responsible for the clinical manifestations of HBSS/sickle cell disease.

Clinicopathologic Features

Patients with HBSS are symptomatic from childhood with disease manifesting as severe hemolytic anemia and signs and symptoms associated with multi-organ damage commonly involving bones, spleen, kidneys, and central nervous system.

In hypoxic states, patients experience bone and joint pain secondary to vaso-occlusive crisis. Kidney damage manifests as hematuria in early stages and can progress gradually to chronic renal failure later in life. Pulmonary involvement can present in the form of acute chest syndrome characterized by chest pain, tachypnea, and wheezing. Neurologic complications can lead to the development of stroke.

LABORATORY FINDINGS

Patients usually have a moderate-to-severe degree of normocytic normochromic anemia with hemoglobin levels between 6-8 g/dL. Reticulocyte count is elevated. Hematocrit is decreased. Peripheral smear morphology shows a variable proportion of reversible and irreversible sickle cells and a moderate degree of target cells (codocytes). Howell-Jolly bodies can be seen in patients with functional asplenia. Iron studies, if performed to rule out concurrent iron deficiency, will usually show increased serum iron, normal total iron binding capacity, and normal % saturation. Leukocytosis with neutrophilia is present to some degree in all patients (WBC 12-20K/ μ L). Counts greater than 20K/ μ L are indicative of infection.

Solubility testing (SICKLEDEX, SickleScreen, or SICKLEQUIK) serves as a rapid, low-cost screen in patients suspected of having sickle cell disease. If positive, more definitive/confirmatory testing should be done. Solubility test cannot differentiate between sickle cell trait and sickle cell anemia. False negative, as well as false positive results, are common.

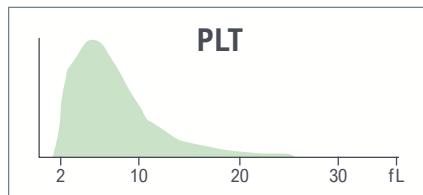
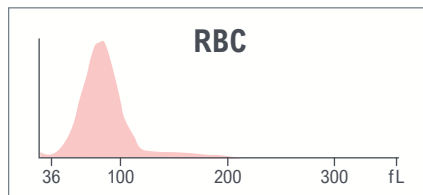
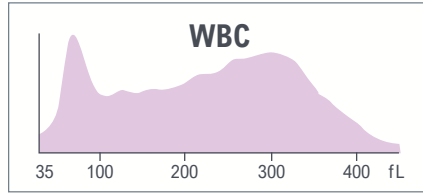
Hemoglobin electrophoresis, a definitive method used for the diagnosis of sickle cell disease, typically shows predominance of HbS = 80% to 95%, variable HbF = 2% to 20%, HbA2 = <3.6%, and no HbA.

CBC parameters indicate Leukocytosis, microcytic anemia with anisocytosis, and thrombocytosis with low MPV.

Abnormal patterns were observed on the WBC histogram with elevated area for Monocytes/Eosinophils/Basophils.

Yellow indicates an action limit is exceeded.

Test	Result	Flags
WBC	17.0	H
UWBC	17.0	H
RBC	2.93	L
HGB	7.8	aL
HCT	23.3	L
MCV	79.4	
MCH	26.8	
MCHC	33.7	
RDW	21.7	aH
RDW-SD	60.8	H
PLT	428	H
MPV	7.1	L





Test	Result	Flags
NE	69.8	
LY	16.6	
MO	8.2	
EO	4.6	
BA	0.8	
NE#	11.8	H
LY#	2.8	
MO#	1.4	H
EO#	0.8	aH
BA#	0.1	
NRBC	0.8	H
NRBC#	0.14	aH
MDW	20.09	

The results of the WBC automated differential show neutrophilia, monocytosis, eosinophilia, and high NRBC.



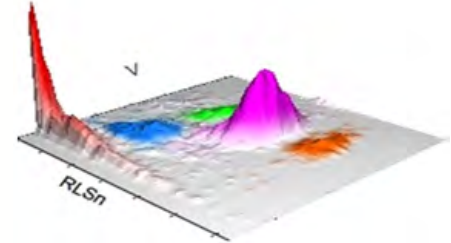


LEUKOCYTES



Suspect messages
• Left Shift

WBC Analysis 5PD1
3D Surface plot



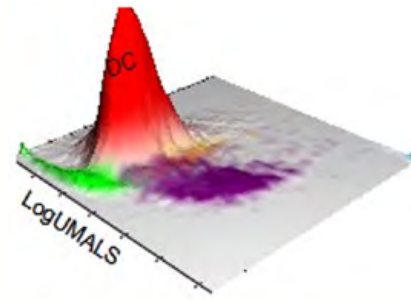
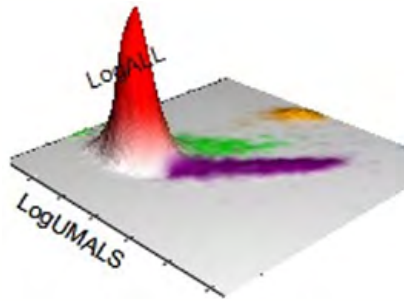
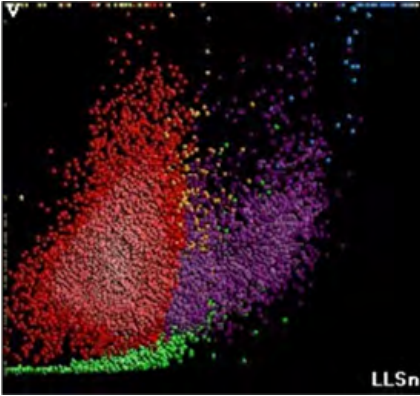
5PD1 plot (Scatter vs. Volume) and 5PD2 plot (Opacity vs. Volume) show abnormal pattern with red population suggestive of the presence of NRBC.

	NE		LY		MO		EO	
	Mean	SD	Mean	SD	Mean	SD	Mean	SD
V	156	24.49 ↑	89	23.65 ↑	161	22.41	169	20.34
C	146	8.40	113	20.35	123	7.41	148	3.94
MALS	130	21.70	68	20.03	81	13.04	191	9.23
UMALS	134	21.60	67	22.13	92	12.78	201	10.30
LMALS	122	24.12	62	22.84	67	17.73	177	10.22
LALS	158	52.74	38	13.96	72	33.73	197	41.84
AL2	143	23.28	72	12.56	126	15.74	127	11.32

The values of Cell Population Data show increased @NE Volume SD and increased @LY Volume SD as compared with normal specimen.



AUTOMATED RETICULOCYTE ANALYSIS




High Retic and IRF, low MRV. 3D dataplot Log ALL vs log UMALS shows distinct orange population—@Unghosted Cells (@UGC), which may indicate the presence of RBC abnormalities.

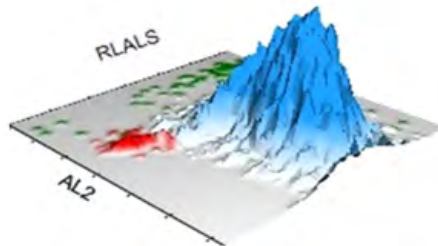
- @UGC 2.03%
- @UGC# 0.06

Test	Result	Flags
RET	7.20	H
RET#	0.2109	H
MRV	93.5	L
IRF	0.61	H

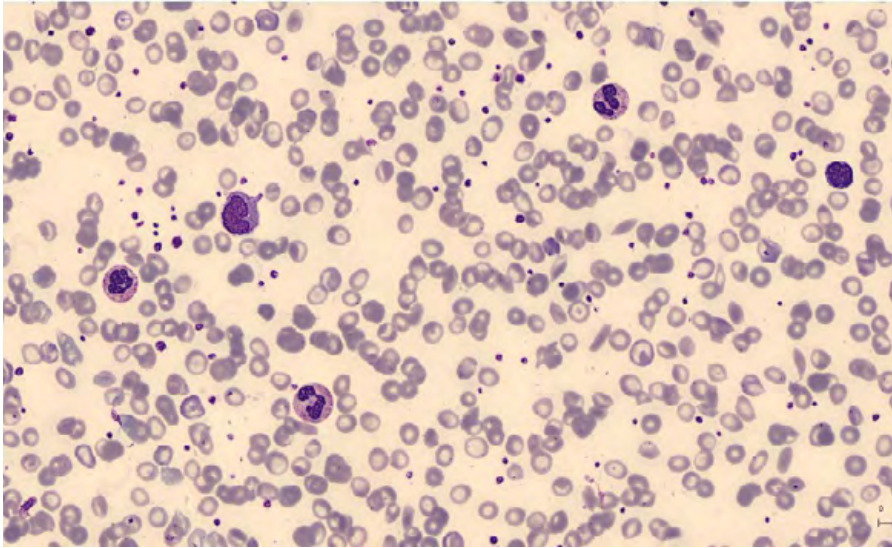
NRBC



NRBC1 plot shows distinct NRBC population (in red).



BLOOD SMEAR



Manual Differential	
Neutrophils	69
Band Neutrophils	0
Lymphocytes	16
Monocytes	8
Eosinophils	5
Basophils	1
Metamyelocytes	0
Myelocytes	0
Promyelocytes	0
Immature Granulocytes	1
Atypical Lymphocytes	0
Blast	0
NRBC	0.3

Summary Results

- > Leukocytosis with neutrophilia, monocytosis, and eosinophilia
- > Microcytic anemia with anisocytosis, high NRBC
- > Thrombocytosis with low MPV
- > Abnormal pattern observed on WBC histogram with elevated area for Monocytes/Eosinophils/Basophils.
- > 5PD1 plot (Scatter vs. Volume) and 5PD2 plot (Opacity vs. Volume) show anisocytosis of neutrophils and lymphocytes and an abnormal pattern with a red population suggestive of the presence of NRBC
- > High Retic and IRF—low MRV. @UGC 2.03%
- > The peripheral blood smear shows a marked anisocytosis with abundant target cells and some sickle cells

DIAGNOSIS: HEMOGLOBIN SS DISEASE/ SICKLE CELL ANEMIA/SICKLE CELL DISEASE



Benign Categories

Lymphoid Neoplasms

Myeloid Neoplasms/
Myelodysplastic Syndromes

Red Blood Cell Disorders





CASE 3 | SICKLE CELL TRAIT

Disease Description

Sickle cell trait (SCT), like sickle cell anemia, is caused by sickle hemoglobin (HbS) resulting from a point mutation in the beta-globin gene that replaces A with T at codon 6 of the beta hemoglobin chain; however, unlike sickle cell disease (SCD) in which both globin genes are mutated, individuals with sickle cell trait have only one abnormal hemoglobin beta gene allele.

Because there is at least one normal beta globin gene that allows for production of HbA, individuals with SCT do not usually experience the severe disease manifestations associated with SCD such as vaso-occlusive crises and severe hemolytic anemia.

Clinicopathologic Features

Individuals with SCT are usually asymptomatic and lead a normal life similar to those in the general population without this abnormality. It is only when they are exposed to conditions leading to oxidative stress, hypoxia infection, dehydration, hypothermia, high levels of 2,3-diphosphoglycerate, etc., the red cells show sickling like that we see in patients with SCD.

Some patients may show hematuria. Splenic infarcts due to chronic episodes of ischemia are seen in some. Patients may show increased risk of developing renal medullary carcinoma.

LABORATORY FINDINGS

Complete Blood Count data may show no abnormalities or mild normocytic normochromic anemia. RBC morphology is normal. No sickle cells are seen. Reticulocyte count may or may not be elevated.

Solubility testing (SICKLEDEX, SickleScreen, or SICKLEQUIK) serves as a rapid, low-cost screen for patients suspected of having sickle cell disease. If positive, more definitive/confirmatory testing should be done. Solubility test cannot differentiate between sickle cell trait and sickle cell anemia. False negative, as well as false positive results, are common.

Hemoglobin electrophoresis, a definitive method used for the diagnosis of sickle cell disease or SCT typically shows: HbS = 35% to 45%, HbF = <1%, HbA2 = 1% to 3%, HbA = 50% to 55%.

CBC parameters indicate leukocytosis, macrocytic hyperchromic anemia with anisocytosis, and thrombocytosis.

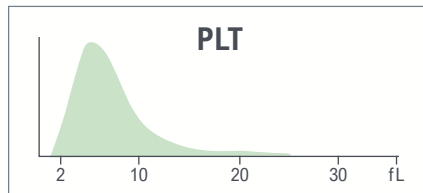
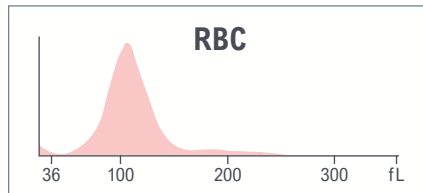
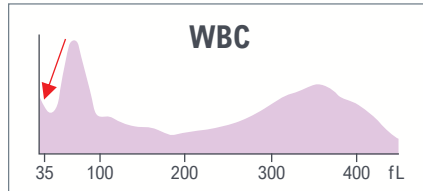
WBC histogram shows interference in the left part of the histogram.

Thrombocytosis with low MPV.

Platelet-related parameters flagged with R due to system message PLT Clumps.

Yellow indicates an action limit is exceeded.

Test	Result	Flags
WBC	12.5	H
UWBC	12.5	H
RBC	2.38	L
HGB	9.0	L
HCT	26.2	L
MCV	109.9	aH
MCH	37.6	aH
MCHC	34.2	
RDW	17.7	H
RDW-SD	66.5	H
PLT	745	R H
MPV	7.4	R



System messages
• PLT Clumps

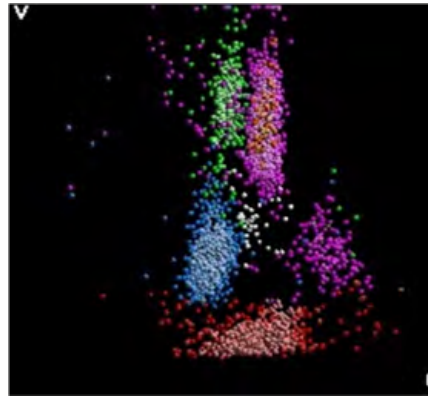

Test	Result	Flags
NE	65.9	
LY	23.1	
MO	8.6	
EO	1.5	
BA	0.9	
NE#	8.3	H
LY#	2.9	
MO#	1.1	
EO#	0.2	
BA#	0.1	
NRBC	0.2	
NRBC#	0.03	

The results of the WBC automated differential show neutrophilia.



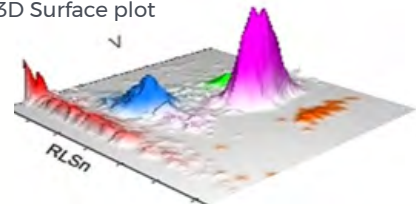


LEUKOCYTES



Suspect message
 • Giant Platelets
 System message
 • PLT Clumps

WBC Analysis 5PD1
 3D Surface plot

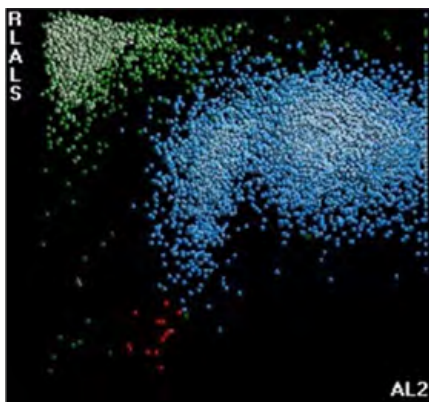


5PD1 plot (Scatter vs. Volume) and 5PD2 plot (Opacity vs. Volume) show abnormal patterns with red population, which can be Giant Platelets/Platelet Clumps as indicated by instrument messages.

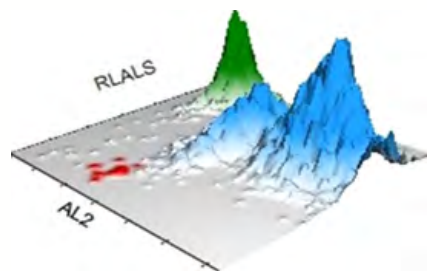
	NE		LY		MO		EO	
	Mean	SD	Mean	SD	Mean	SD	Mean	SD
V	176 ↑	20.45	92	17.58	190 ↑	24.68 ↑	184	18.67
C	146	7.99	115	9.49	125	10.05	146	3.96
MALS	137	11.88	83	16.26	96	11.10	200	5.78
UMALS	143	11.59	86	18.20	106	13.28	212	5.70
LMALS	127	14.36	73	18.86	81	13.62	184	8.16
LALS	167	36.60	39	11.38	105	28.10	178	48.14
AL2	157	14.18	77	10.49	143	13.86	129	10.03

The values of Cell Population Data show increased @NE Volume Mean, increased @MO Volume Mean, and increased @MO Volume SD as compared with normal specimen.

NRBC

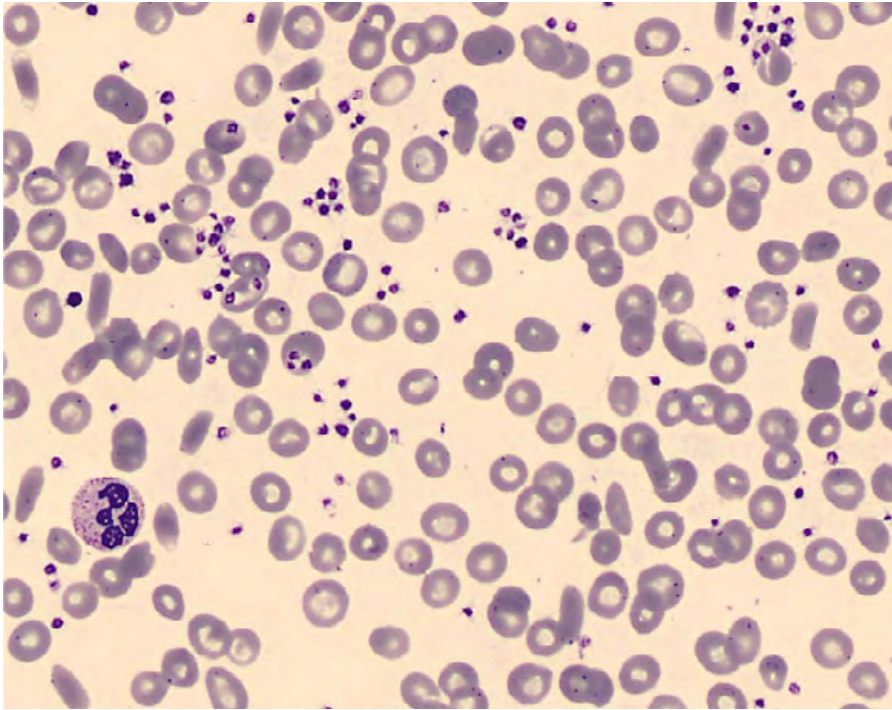


NRBC1 plot shows green population, which is a typical pattern of platelet clumps.



For research use only. Not for use in diagnostic procedures.
 @ - Research Use Only (RUO) parameters

BLOOD SMEAR



Manual Differential	
Neutrophils	64.5
Band Neutrophils	0
Lymphocytes	25
Monocytes	8.5
Eosinophils	0.5
Basophils	0
Metamyelocytes	
Myelocytes	
Promyelocytes	
Immature Granulocytes	0
Atypical Lymphocytes	1.5
Blast	
NRBC	

Summary Results

- › Leukocytosis and neutrophilia
- › Macrocytic hyperchromic anemia with anisocytosis
- › WBC histogram shows interference in the left part of the histogram
- › 5PD1 plot (Scatter vs. Volume) and 5PD2 plot (Opacity vs. Volume) show abnormal patterns with a red population and the NRBC1 plot displays a green population. All these patterns are compatible with the PLT Clumps flag
- › Thrombocytosis with low MPV, R flag due to PLT Clumps system message
- › Multiple RBC abnormalities: target cells, and ovalocytes
- › PLT clumps were observed on the blood smear

Comments:

Platelet clumps may be responsible for a false decrease in platelet counts and pseudo thrombocytopenia. A redraw of blood in a non-EDTA blood anticoagulant such as citrate is recommended.

DIAGNOSIS: SICKLE CELL TRAIT





CASE 4 | VITAMIN B12 DEFICIENCY

Disease Description

Vitamin B12 is involved in production of both DNA and red blood cells. As human cells do not produce Vitamin B12, it must be obtained in the diet. Foods such as eggs and seafood are naturally rich in B12, and many other foods are fortified with B12. B12 deficiency may be the result of veganism, gastrectomy, certain medications that interfere with absorption, or small intestinal lesions. Especially in Western countries, severe vitamin B12 deficiency can be caused by (Addisonian) pernicious anemia, where the intestines do not properly absorb vitamin B12.

Clinicopathologic Features

Low levels of B12 can cause weakness and fatigue, dizziness, neurological involvement such as memory loss, and tingling in the extremities. Vitamin B12 deficiency has an insidious onset with gradually progressive symptoms and signs of anemia, mild jaundice, glossitis (beefy-red sore tongue), and angular stomatitis. Mild symptoms of malabsorption with loss of weight are also seen.

LABORATORY FINDINGS

Macrocytic anemia (MCV >98 fL and often as high as 120-140 fL in severe cases). Evidence of megaloblastic anemia with decreased RBCs, low Hgb, and Hct are also seen. RBCs are of abnormal shape. Total white cells and platelets may be reduced, especially in severely anemic patients. A proportion of the neutrophils show hyper-segmented nuclei (with six or more lobes). Giant and abnormally shaped metamyelocytes are characteristic.



CBC parameters indicate macrocytic anemia with anisocytosis and thrombocytopenia.

There is a concomitant Vitamin B12 and iron deficiency.

System messages “PLT Inter: Debris” and “RBC-PLT overlap”.

Abnormal Plt histogram with high-end and low-end interference, resulting in PLT count and MPV flagged with “R.”

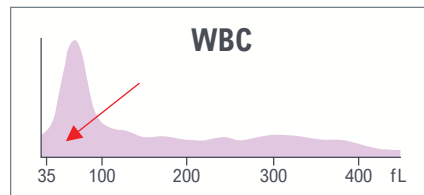
WBC histogram shows interference at 35 fL threshold.

The elevated left part of the RBC histogram suggests the potential presence of RBC fragments.

Red indicates a critical limit is exceeded

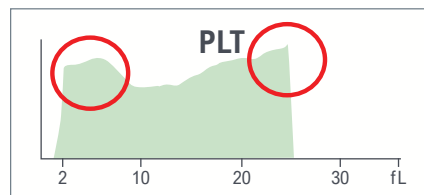
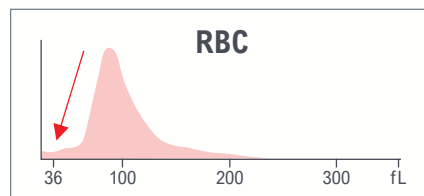
Yellow indicates an action limit is exceeded.

Test	Result	Flags
WBC	8.3	
UWBC	8.3	
RBC	3.00	L
HGB	10.0	L
HCT	29.2	L
MCV	97.2	H
MCH	33.3	
MCHC	34.3	
RDW	22.7	aH
RDW-SD	74.8	H
PLT	27	RaL
MPV	6.5	R L



System messages

- PLT Inter: Debris
- RBC-PLT overlap


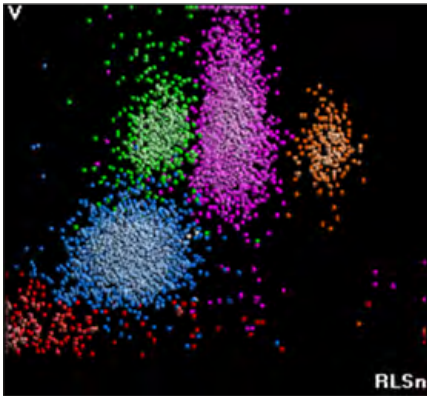


Test	Result	Flags
NE	46.7	
LY	40.8	
MO	9.0	
EO	3.4	
BA	0.1	L
NE#	3.9	
LY#	3.4	H
MO#	0.7	
EO#	0.3	
BA#	0.0	
NRBC	8.0	cH
NRBC#	0.67	cH
MDW	22.33	

The results of the WBC automated differential show lymphocytosis and high NRBC.



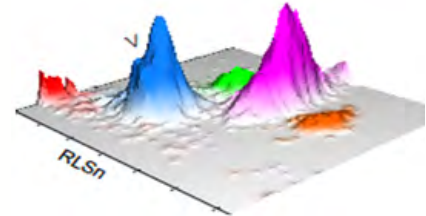
LEUKOCYTES



Suspect messages

- Imm Grans
- Left Shift

WBC Analysis 5PD1
3D Surface plot



5PD1 plot (Scatter vs. Volume) and 5PD2 plot (Opacity vs. Volume) show elongated neutrophil population as indicated by the instrument message and red population suggestive of the presence of NRBC.

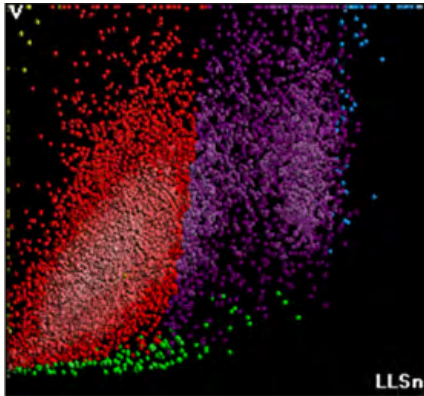
	NE		LY		MO		EO	
	Mean	SD	Mean	SD	Mean	SD	Mean	SD
V	178 ↑	28.70 ↑	92	16.12	172	23.38 ↑	161	16.44
C	143	8.70	115	8.94	124	6.59	148	7.54
MALS	138	11.27	76	16.05	91	12.58	196	8.89
UMALS	143	14.32	78	18.08	97	13.47	208	10.10
LMALS	129	12.31	67	19.28	82	15.05	180	10.23
LALS	170	45.44	37	10.68	103	31.73	189	51.27
AL2	159	18.32	77	11.94	137	16.60	130	11.58

The values of Cell Population Data show increased @NE Volume Mean, increased @NE Volume SD, and increased @MO Volume SD as compared with normal specimen.

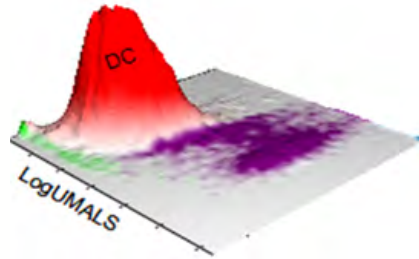
For research use only. Not for use in diagnostic procedures.
@ - Research Use Only (RUO) parameters



AUTOMATED RETICULOCYTE ANALYSIS

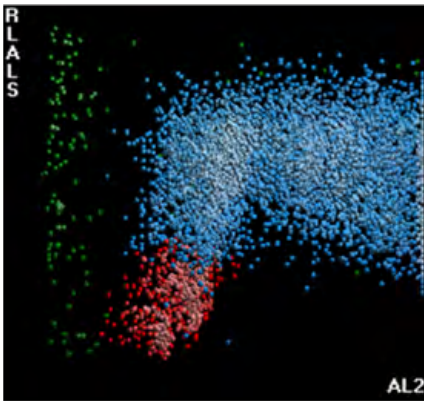


High Retic, MRV, and IRF.

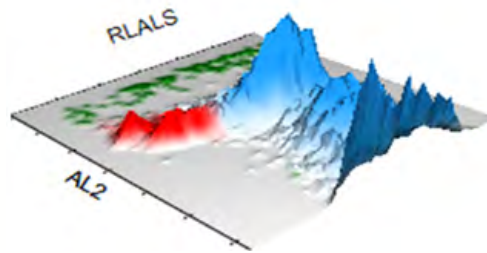


Test	Result	Flags
RET	7.89	H
RET#	0.2369	H
MRV	148.9	H
IRF	0.73	H

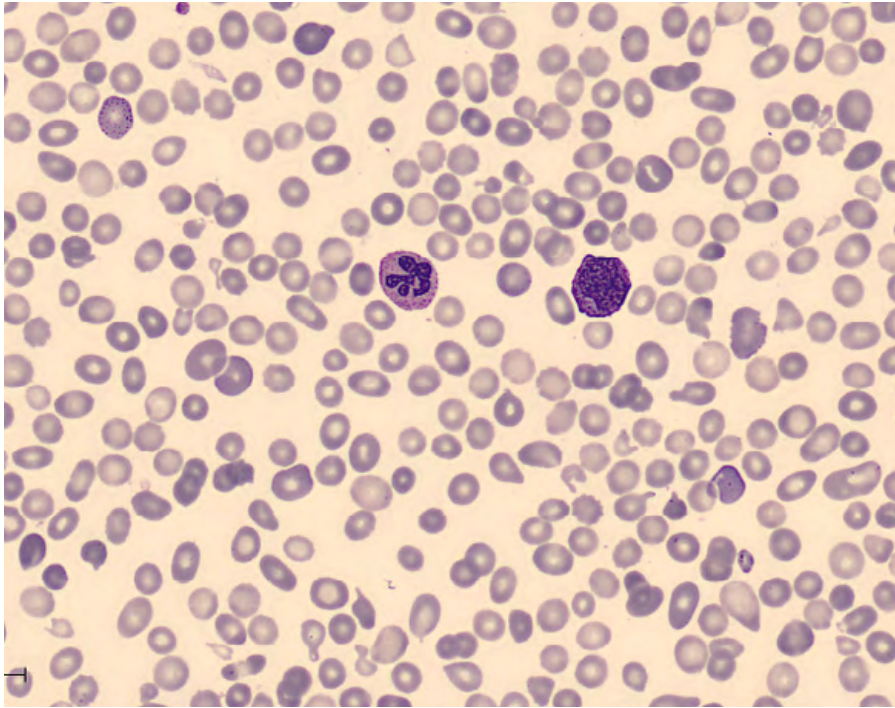
NRBC



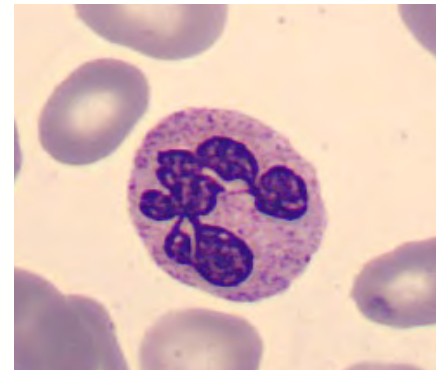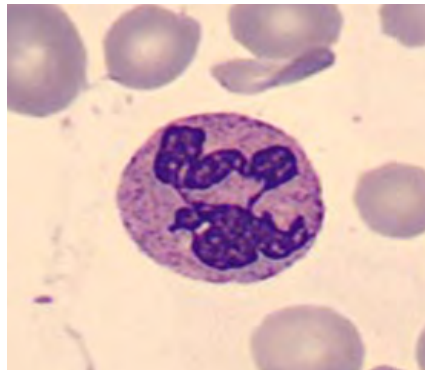
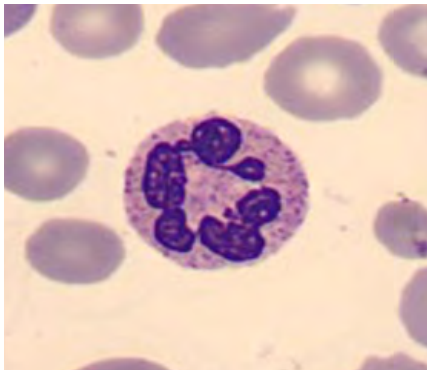NRBC1 plot shows distinct NRBC population (in red).



BLOOD SMEAR



Manual Differential	
Neutrophils	36
Band Neutrophils	1
Lymphocytes	43.5
Monocytes	8
Eosinophils	4
Basophils	0.5
Metamyelocytes	1
Myelocytes	6
Promyelocytes	0
Immature Granulocytes	0
Atypical Lymphocytes	0
Blast	0
NRBC	10



Summary Results

- › Macrocytic anemia with anisocytosis and high NRBC. High Retic, MRV, and IRF
- › Thrombocytopenia with abnormal PLT histogram with high-end and low-end interference, resulting in platelet count and MPV flagged with R
- › Moderate lymphocytosis
- › SPD1 and SPD2 dataplots show abnormal neutrophil population and red population at the bottom of the plot suggestive of the presence of NRBC
- › Hypersegmented neutrophils
- › Abnormal RBC - ovalocytes, echinocytes, dacryocytes
- › RBC fragments observed on the blood film, triggering the system message RBC-PLT Overlap
- › Diagnosis from hospital: B12 deficiency, iron deficiency, intramedullary hemolysis

DIAGNOSIS: VITAMIN B12 DEFICIENCY, IRON DEFICIENCY, INTRAMEDULLARY HEMOLYSIS





CASE 5 | IRON DEFICIENCY ANEMIA WITH PLATELET CLUMPS

Disease Description

Iron-deficiency anemia is the most commonly diagnosed type of anemia. Low blood iron can be caused by blood loss, for example during menstruation or in frequent blood donors, low dietary iron intake, iron malabsorption, and pregnancy. Severe iron deficiency anemia can lead to abnormal heartbeat, low birth weight, and pregnancy and growth complications. Iron is available in foods such as red meats, green leafy vegetables, and fortified grains as well as in dietary supplements. Increasing dietary vitamin C consumption concurrent with iron-rich foods can enhance iron absorption.

Clinicopathologic Features

The major adaptations to anemia are in the cardiovascular system and the hemoglobin dissociation curve.

The presence or absence of clinical features can be considered under four major headings:

- › Speed of onset
- › Severity: Symptoms and signs are usually present when the HGB level is less than 10 g/dL
- › Age
- › Hemoglobin O₂ dissociation curve

Mild cases are often asymptomatic, but symptoms may include shortness of breath, weakness, lethargy, palpitation, and headaches.

LABORATORY FINDINGS

The most useful classification is based on red cell indices and divides the anemia into microcytic, normocytic, and macrocytic. Patients suffering from iron deficiency anemia present with low hemoglobin, microcytosis, hypochromia, and anisocytosis.



CBC parameters indicate microcytic hypochromic anemia and thrombocytopenia.

WBC histogram shows an abnormal pattern with the elevation in the area of 35 fL.

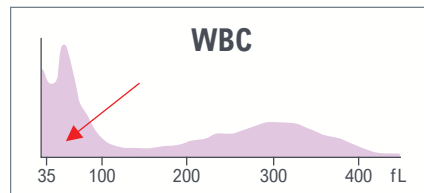
Due to this interference and system message “Cellular interference,” the results of WBC and UWBC are flagged with an “R” flag for review.

The PLT histogram shows an abnormal pattern with the elevation in the right part of the histogram, probably due to the presence of PLT clumps, as indicated by the system message.

As with the WBCs, this leads to an R flag for platelet-related results.

Yellow indicates an action limit is exceeded.

Test	Result	Flags
WBC	5.6	R
UWBC	8.3	R
RBC	4.50	
HGB	9.6	L
HCT	30.3	L
MCV	67.3	aL
MCH	21.4	L
MCHC	31.8	L
RDW	16.1	
RDW-SD	36.8	
PLT	83	R L
MPV	10.6	R

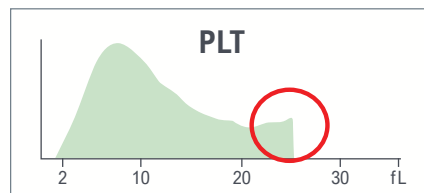
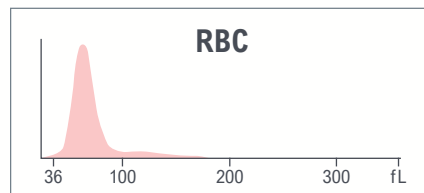


Suspect messages

- Giant Platelets

System messages

- Cellular Inter-Platelet Clumps

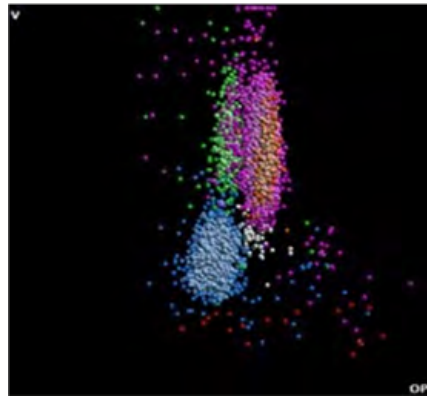
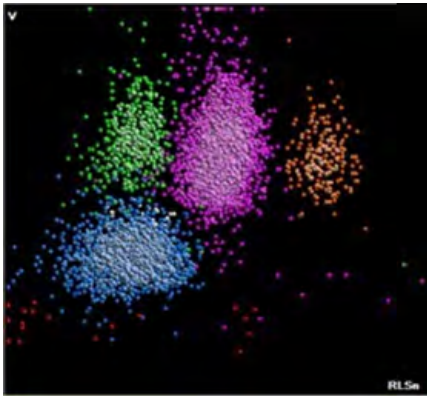


Test	Result	Flags
NE	64.4	
LY	25.9	
MO	6.3	
EO	2.6	
BA	0.8	
NE#	3.6	R
LY#	1.5	R
MO#	0.4	R
EO#	0.1	R
BA#	0.0	R
NRBC	0.1	
NRBC#	0.00	R

The absolute results of the WBC automated differential are flagged with R, because WBC count is flagged for review.

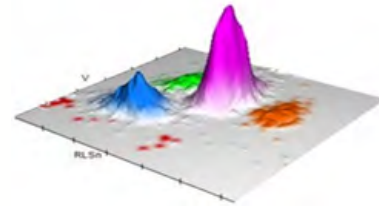


LEUKOCYTES



Suspect messages
 • No instrument messages related to WBC differential

WBC Analysis 5PD1
 3D Surface plot



5PD1 plot (Scatter vs. Volume) and 5PD2 plot (Opacity vs. Volume) do not show any abnormalities.

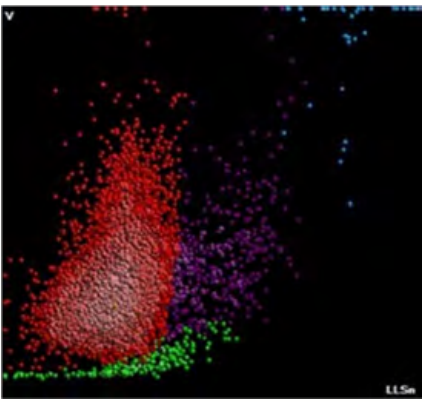
	NE		LY		MO		EO	
	Mean	SD	Mean	SD	Mean	SD	Mean	SD
V	158	20.51	90	13.48	169	21.43	156	17.99
C	153	6.28	124	8.81	133	7.72	155	4.04
MALS	132	10.89	75	17.22	78	14.24	194	10.38
UMALS	129	12.04	77	19.68	89	15.66	206	10.75
LMALS	130	14.67	67	20.38	64	17.78	178	12.70
LALS	189	34.07	37	10.11	83	29.59	183	40.38
AL2	140	11.00	69	8.68	119	11.58	121	9.11

The values of Cell Population Data do not show abnormalities as compared to normal specimen.

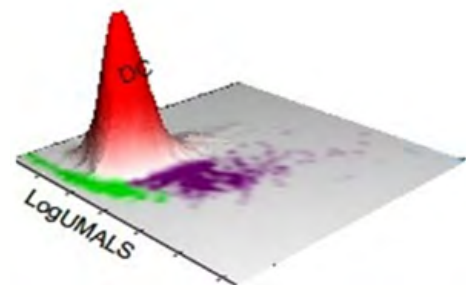
For research use only. Not for use in diagnostic procedures.
 @ - Research Use Only (RUO) parameters



AUTOMATED RETICULOCYTE ANALYSIS




Low MRV.

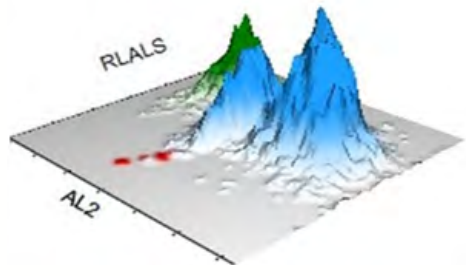


Test	Result	Flags
RET	1.26	
RET#	0.0568	
MRV	90.0	
IRF	0.46	

NRBC

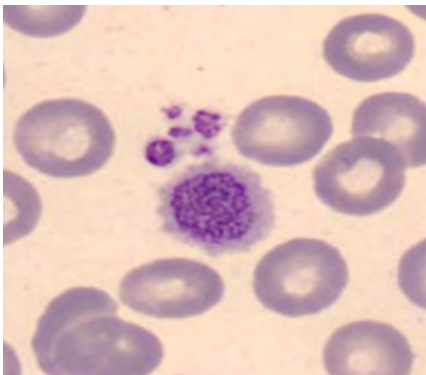
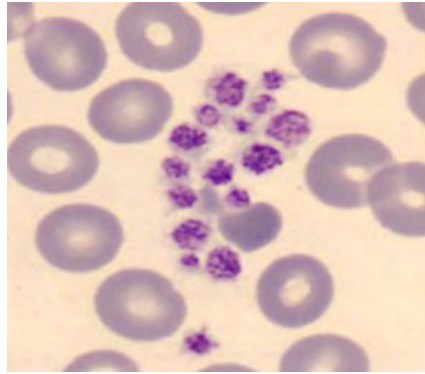
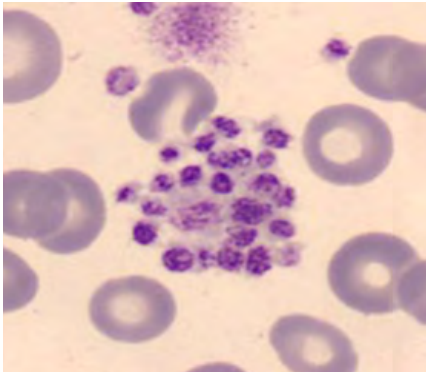


NRBC1 plot shows green population in the top-left corner, which may represent Platelet Clumps as indicated by instrument message.





BLOOD SMEAR



Manual Differential	
Neutrophils	62
Band Neutrophils	2
Lymphocytes	27
Monocytes	6
Eosinophils	1
Basophils	0.5
Metamyelocytes	
Myelocytes	1.5
Promyelocytes	
Immature Granulocytes	1.5
Atypical Lymphocytes	
Blast	
NRBC	

Comments:

Few large PLT, Platelet clumps
Hypochromia, Elliptocytes

Summary Results

- > Microcytic hypochromic anemia and low MRV
- > WBC histogram shows an abnormal pattern with interference in the area of 35 fL. Few Immature Grans were observed on the blood film
- > Independently of the iron deficiency anemia, this patient presented with platelet clumps possibly as a pre-analytical phase deficiency
- > (Pseudo)Thrombocytopenia with an abnormal PLT histogram. Due to the “Platelet clumps” flag, the result of the PLT count is flagged with an “R” for review
- > Few large platelets and platelet clumps were observed on the slide

**DIAGNOSIS: IRON DEFICIENCY ANEMIA PLATELET CLUMPS
MODERATE INFECTION IN THE ARM**



Special thanks to the Beckman Coulter associates involved in authoring and assembling this remarkable casebook. Their invaluable contributions have greatly enriched our collection and solidified our gratitude:

Elena Sukhacheva, Ph.D.

Beckman Coulter Eurocenter
Nyon, Switzerland

Ahmed Bentahar, M.D., Ph.D.

Beckman Coulter, Miami, FL, USA

Mirta Gamez, MT(ASCP), CLS

Beckman Coulter, Brea, CA, USA

Kanochia Johnson, MT(ASCP), CLS, MPM

Beckman Coulter, Brea, CA, USA

Learn more at

[beckmancoulter.com/hematology](https://www.beckmancoulter.com/hematology)

© 2023 Beckman Coulter, Inc. All rights reserved. Beckman Coulter, the stylized logo, and the Beckman Coulter product and service marks mentioned herein are trademarks or registered trademarks of Beckman Coulter, Inc. in the United States and other countries.

For Beckman Coulter's worldwide office locations and phone numbers, please visit www.beckmancoulter.com/contact

BR-369701 | 2023-11794, 2023-11797, 2023-11649, 2023-11791, 2023-11793

